

Comparative study of Selenium Nanoparticles versus Metformin Drug in Polycystic Ovary Syndrome Induced in Adult Albino Rat Model: A Histological, Immunohistochemical and Biochemical Study

Original
Article

Ghada Nady¹, Mohamed Emad El-Din¹, Mohamed Hafez¹, Asmaa Sayed¹ and Marwa Abdelgwad²

¹Department of Anatomy and Embryology, ²Department of Medical Biochemistry and Molecular Biology, Faculty of Medicine, Cairo University, Egypt

ABSTRACT

Introduction: Through scientific literature, polycystic ovary syndrome (PCOS) is a relatively common endocrine disorder among young women and leads to metabolic problems associated with the onset of infertility. Selenium nanoparticles (SeNps) are an essential trace element playing vital role in the physiological processes. It was ignored as a therapeutic agent in the past, but recently it was revealed that it must be obtained from diet as it cannot be produced by organisms.

Aim of Study: The present study might draw attention to the effective and promising role of Selenium nanoparticles (SeNps) in the treatment of PCOS as compared with the metformin.

Materials and Methods: Forty adult female rats were enrolled and randomly divided into four equal groups; control group received no manipulation, untreated PCOS group, metformin treated group and SeNps treated group. Animals were sacrificed and biochemical, molecular and histopathological analysis were performed.

Results: Both metformin and SeNps succeeded in restoring normal follicular capacity of the affected ovaries with PCOS regarding ; the histological follicular restoration, hormonal and blood glucose level regulation, immunological and biochemical improvement . However, SeNps was more superior in enhanced the oxidative status enzymes, where it significantly reduced the elevated GPx and SOD tissue levels compared to metformin group, and decreased tissue inflammatory mediators TNF-alpha and IL-1 in the ovarian tissue.

Conclusion: The extent of ovarian regeneration, excreted by selenium nanoparticles (SeNPs) not only comparable to that of metformin drug but also it has a great privilege as an alternative therapy of PCOS especially in intolerant patients to oral hypoglycemic drugs.

Received: 20 September 2022, **Accepted:** 22 December 2022

Key Words: Metformin, ovaries, PCOS, selenium nanoparticles (SeNPs).

Corresponding Author: Ghada Nady Ouais, MD, Department of Medical Biochemistry and Molecular Biology, Faculty of Medicine, Cairo University, Egypt, **Tel.:** +20 12 2532 0845, **E-mail:** ghada.nady@kasralainy.edu.eg

ISSN: 1110-0559, Vol. 47, No. 1

INTRODUCTION

Polycystic ovary syndrome (PCOS) is one of the most frequently diagnosed endocrinopathy in women at reproductive age^[1]. There are several definitions of PCOS; the most widely used is the Rotterdam criteria, based on the fulfillment of two out of three of the following conditions, hyperandrogenemia, oligo- or amenorrhea, and sonographic visualization of polycystic ovaries^[2]. The use of antioxidants in the management of PCOS is attracting lots of interests. Antioxidant supplementation has shown to improve insulin sensitivity and other health threatening conditions in women with PCOS^[3].

As a potent antioxidant, selenium (Se) has a role in biochemical and pharmacological protection against various inflammatory and oxidative stress mediated conditions, being incorporated into selenoproteins as selenocysteine (Sec), it represents an important part of the active center of most enzymatic activities. Selenoproteins

have the unique ability to trap H₂O₂ and use the resulting selenic acid to form specific disulfide bonds in the presence of GSH and are thus well suited for controlling the formation of disulfide bonds with specific Cyst residues^[3].

With the emergence of nanotechnology and its wide application in medicine, selenium nanoparticles (SeNPs), being highly specific due to their sizes (1-100 nm) can be used instead of selenium salts as a bulk material to potentiate its bioavailability and pharmacological effects^[4].

Thus, this study was designed to detect the role of metformin in PCOS and compare it with a newly emerging therapy, selenium nanoparticles (SeNPs), in experimentally-induced polycystic ovary in rats.

MATERIAL AND METHODS

Chemicals

1. Testosterone ethanoate (TE (Trade name: Cidotestone ampoules 250 mg/ml, purchased from

CID Co., Cairo, Egypt (cat # T323445). Each ampoule was diluted in 25 ml sesame oil to form concentration 10 mg/ml. The drug was prepared for intraperitoneal injection^[5].

2. Metformin tablets Trade name: Cidophage tablets 500mg was purchased from CID Co., Cairo, Egypt (cat # M12245). Tablets were crushed and dissolved in carboxymethyl cellulose (CMC) solution and prepared for gastric gavage^[6].
3. SeNps (98% (SeNP was purchased from Nanotech chemical CO for Photo-Electronics, Cairo, Egypt (cat # S3707) in the form of a liquid suspension (98%), and was prepared for intraperitoneal injection. SeNps were synthesized by oxidation reactions, it has sheet like appearance, its concentration is 7.8 ppm, and the average size of each particle is 40±5 nm.

Experimental design

Animal groups

The study was conducted on forty adult female albino rats, from six to eight weeks old and weighting 150-200 g. The rats were provided by the Laboratory Animal House, Kasr el Ainy Faculty of Medicine, Cairo University. It was approved by Cairo University Institutional Animal Care and Use Committee (CU-IACUC). The code number: MS-112-2020.

The rats were provided with ordinary rat chow and were housed in wire mesh cages (4 rats/ cage) at a controlled temperature ($24 \pm 1^\circ\text{C}$). The animals were given food and water ad libitum. The experiment was conducted in accordance with the guidelines of the committee of laboratory animals at Kasr El-Ainy School of Medicine. They were randomly allocated into two categories: control animals (10 rats) and animals subjected to PCOS induction (30 rats).

Group I (normal control): received no manipulation and consisted of 10 rats and were sacrificed at day zero of the experiment.

Group II (PCOS): 10 Rats allocated for PCOS induction were subjected to daily intraperitoneal injection of testosterone ethanoate solution 1mg/kg/day for 14 days, at noon every day^[5]. The day in which PCOS induction was established, through biochemical analysis of blood samples obtained from the rats, was considered as day zero of the experiment. They were sacrificed at day zero of the experiment.

Group III (metformin): consisted of 10 rats with PCO, they received 30mg/kg/day metformin for 21 days, starting at day zero, through gastric gavage^[6], and were sacrificed at day 22. **Group IV** (Selenium nanoparticles) :Consisted of 10 rats with PCO, that received 1 mg/kg/day selenium nanoparticles for 21 days, starting at day zero, through intraperitoneal injection^[7], and were sacrificed at day 22 of the experiment.

Vaginal smear

To confirm fertility of the selected rats, vaginal wet mount cytological examination was done for 15 successive days at noon every day, by vaginal swabbing using a cotton swab. Each swab was spread on a microscopic glass slide and allowed to air dry. The slides were stained with toluidine blue O stain, and examined under light microscope. Only rats starting estrous phase of the cycle were employed in the experiment showing large a nucleated cornified epithelial cells (Figure 1)^[8]. While rats in metestrous phase of the cycle, that showed abundance of leucocytes (Figure 2), as described by the authors, were excluded from the experiment.

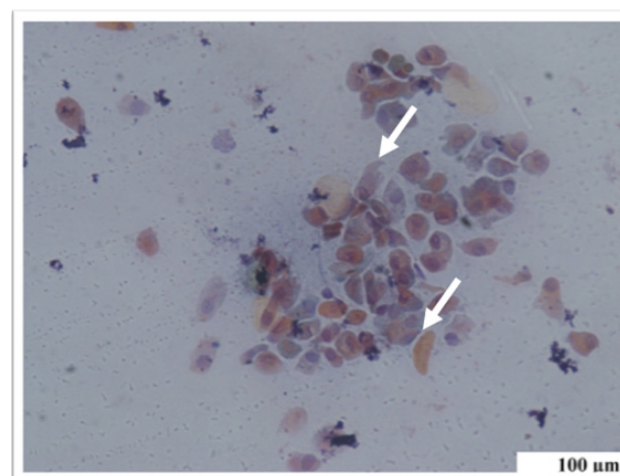


Fig. 1: A photomicrograph of astained vaginal smear from a female albino rat at the estrous phase, showing predominance of large cornified cells (white arrows) arranged in clumps (Toluidine blue X200).

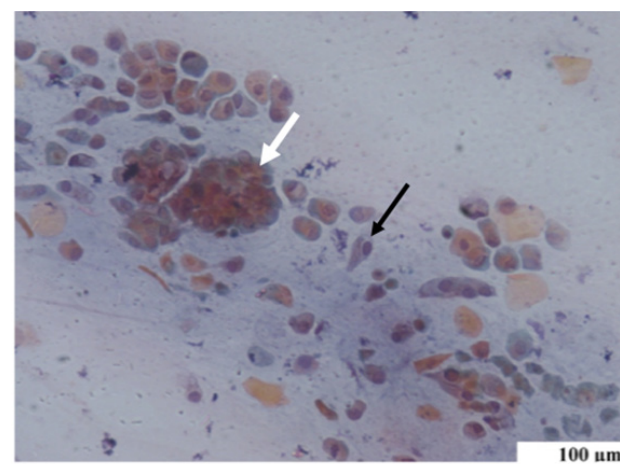


Fig. 2: A photomicrograph of astained vaginal smear from a female albino rat at the metestrous phase, showing predominance of leucocytes (white arrow) and large epithelial cells (black arrow) (Toluidine blue X200) .

Blood biochemical study

At the end of each experiment, blood samples were obtained from each animal (via retro-orbital vein) and were subjected to sera analysis of the following: total testosterone level, follicular stimulating hormone (FSH)

level, luteinizing hormone (LH) level and blood glucose level (BGL).

Scarification and Tissue sampling

Following the blood samples extraction at the end of each experiment, the animals were sacrificed by cervical dislocation, under light ether inhalation, to avoid chemical injury. The ovaries were excised through laparotomy, cleaned of adnexal fats and washed with distilled water to wash out the remaining blood. The right ovaries were allocated for histological and Immunohistochemical studies, while the left ovaries were designated for biochemical and genetic analysis. The right ovaries were obtained from all groups were allocated for light microscopic examination and stained with haematoxylin and eosin (H&E) and other stained with Periodic acid Schiff (PAS)^[9]. Sections were deparafinized in xylene. Then, washed in descending grades of ethanol (100%, 95%, and 70%) two changes 5 minutes each, rehydrated in phosphate buffer saline (PBS) by using a steamer in citrate buffer with pH 6.0 for 15 min and endogenous peroxidase activity was blocked with H₂O₂ in methanol. Sections were pre-treated in citrate buffer (pH 6.0) in a microwave. Sections were incubated at room temperature with rabbit monoclonal TNF-alpha and IL-1. Ultra Vision detection System (Thermo Scientific) was used as follows: sections were incubated with biotinylated goat anti-polyvalent, then with streptavidin peroxidase and finally with DAB plus chromogen. Slides were counterstained with haematoxylin dehydrated in alcohol and xylene and covered with neutral balsam. The slides were visualized under light microscope and the extent of cell immune positivity was assessed in all groups^[10]. The left ovaries were designated for biochemical and genetic analysis.

Assessment of Glutathione peroxidase and Superoxide dismutase by colormetry

One part of the left ovary was preserved in 0.1M phosphate buffer saline (PBS) solution and centrifuged at 1200 rpm/minute for 10 minutes. The supernatant was used to determine tissue level of Glutathione peroxidase (GPx) and Superoxide dismutase (SOD)^[11]. The techniques were done according to the manufacturer's instructions (LAB-SA system, Zymed Laboratories Inc, San Francisco, USA, 95-9643). The enzymes activity in tissue homogenate was measured by the inhibition of nitrobluetetrazolium reduction by O₂-generated by the xanthine/xanthine oxidase system. One SOD or GPx activity unit was defined as the enzyme amount causing 50% inhibition in 1 mL reaction solution per gram tissue protein and the result was expressed in U/mg of tissue.

Real time quantitative PCR of studied genes

Total RNA was extracted from ovary tissue homogenate with Easy pure RNA Kit (transgen, China.catalog no. ER101-01). The quantity and quality were assessed by Beckman dual spectrophotometer (USA). TransScript Green One-StepqRT-PCR SupermixKit, catalog no.AQ211

had been formulated for highly reproducible first-strand cDNA synthesis and subsequent real-time PCR in a single tube in a 48-well plate using the Step One instrument (Applied Biosystem, USA). Normalization for variation in the expression of each target gene was performed referring to the mean critical threshold (CT) values of glyceraldehyde 3-phosphate dehydrogenase (GAPDH) housekeeping gene expression by the $\Delta\Delta C_t$ method. Primers base sequences of the studied genes are listed in (Table 1).

Table 1: Details about the base sequences of the primers used

Gene	Name	Direction and Primer sequence (5'-3')
Keap-1	Kelch-like ECH-associated protein 1	Forward F:5'-TTCGCCTACACGGCCTC-3'
		Reverse: 5'-GAAGTTGGCGATGCCGATG-3'
Nrf2	Nuclear factor E2-related factor 2	Forward: 5'-TCTGACTCCGGCATTCTCACT-3'
		Reverse: 5'-GGCACTGTCTAGCTCTTCCA-3'
HO-1	HemeOxygenase 1	Forward:5'-CGTGCAGAGAATTCTGAGTTC-3'
		Reverse: 5'-AGACGCTTTACGTAGTGCTG-3'
GAPDH (Internal Control)	Glyceraldehyde 3-phosphate dehydrogenase	Forward: 5'-CACCCCTGTGCTGTAGCCATATTC-3'
		Reverse: 5'-GACATCAAGAAGGTGGTGAAGCAG-3'

Histomorphometric study

The quantitative study was performed with Image J analysis computer software system. The specimen preparations of the ovary from each rat were subjected to quantitative studies in 10 non-overlapping microscopic fields randomly picked from each slide. They were examined within the standard measuring frame of a known area equal to 11694.91µm². The following parameters were measured:

1. Mean follicular count: The number of primary, secondary and antral follicles was counted using image J analyser in 5 random fields from each group, with a surface area of 127.64-133.34 µm² under magnification 100, and its mean count was calculated.
2. Optical density of PAS staining in PAS stained sections with magnification 400.
3. Area percent of TNF-alpha immune-reactivity in TNF-alpha immunostained ovarian section with magnification 400.
4. Area percent of IL-1 immune-reactivity in IL-1 immunostained ovarian sections with magnification 400.

Statistical analysis

Statistical analysis was performed using statistical package for the social sciences (SPSS) version 21.0 (IBM Corporation, Somers, NY, USA) statistical software. The data were expressed as means ± standard deviation (SD). Statistical evaluation was done using one-way analysis of

variance (ANOVA). Significance was considered when p value was equal to or less than 0.05 throughout the study.

RESULTS

Histological Results

Hematoxylin and Eosin Stained Sections

H& E stained sections of the control group I showed normal histological architecture of the ovary, consisting of an outer cortex, obliterated by multiple follicles at different stages of development, and an inner medulla. Mature Graafian follicles were observed in most sections consisting of an oocyte surrounded by zona pellucida and corona radiata. The granulosa cell layer was formed of multiple layers of cells lining the follicular cavity separated from theca folliculi by a basement membrane; the follicular cavity was occupied by liquor folliculi (Figures 3 A,B). In the ovarian sections of PCOS group II, they revealed abnormally enlarged ovarian cysts of variable sizes containing acidophilic liquor folliculi in their lumens. The cysts were lined with a markedly thin granulosa layer, multiple degenerated follicles, full of cell debris with the absence of normal developing follicles (Figures 4 A,B). In sections obtained from group III (received metformin) elaborated multiple follicles in different stages of development obliterating the ovarian cortex. The secondary follicles were surrounded with multiple layers of granulosa cells separated from theca layer by a basement membrane. A cystic follicle, a mature Graafian follicle, a corpus luteum and few dilated cysts were encountered in some sections. (Figures 5 A,B). In sections obtained from group IV (received SE Nps), ovarian follicles in different stages of development were encountered. This group displayed an evident ameliorative effect exhibited histological picture nearly similar to its control group and takes the upper hand as compared with the metformin group in regaining of their normal structure (Figures 6 A,B).

Periodic acid Schiff (PAS) reaction

Ovarian sections of control group revealed moderate positive PAS staining in the intercellular spaces between granulosa cells, theca cells and in the granulosa basement membrane (Figure 3C). Ovarian sections of PCOS group II showed weak positive PAS reaction in the intercellular spaces within the granulosa layer, theca layer, and granulosa basement membrane (Figure 4C). Ovarian sections of group III (received metformin) showed strong positive PAS staining in the intercellular spaces between granulosa cells and in the granulosa basement membrane (Figure 5C). Sections of group IV (received SeNps) showed strong positive PAS staining in granulosa basement membranes (Figure 6C).

Immunohistochemical study

Anti- TNF- alpha antibodies

Ovarian sections obtained from control group showed negative immune reaction for TNF-alpha in the cytoplasm of follicular cells, theca cells and medullary stroma

(Figure 3D). While the sections obtained from PCOS group II showed strong positive immune reaction in the cytoplasm of follicular granulosa cell, the theca cell layer and around a degenerating follicle (Figure 4D). In group III (received metformin) moderate immune reaction was detected in most ovarian sections, in the cytoplasm of granulosa cell layer and within intervening stromal cells (Figure 5D). Group IV (received SeNp) showed a negative immune reaction in the cytoplasm of the granulosa cells and moderate reaction in the cytoplasm of theca cells in most stained sections (Figure 6D).

N.B: Brown coloration considers negative reaction and Blue coloration: positive reaction

Anti- interleukin 1 antibodies

In ovarian sections obtained from the control group, the cytoplasm of follicular cells, theca cells and intervening stromal cells showed a negative immune reaction to IL-1 antibodies (Figure 3E). PCOs group II showed moderate positive immune reaction in the cytoplasm of granulosa cell layer around the follicles and degenerating cells inside follicular cavity. (Figure 4E). Ovarian sections from group III (received metformin) showed moderate positive immunostaining to IL-1 antibodies in the cytoplasm of granulosa cells around follicles (Figure 5E). Group IV (received SeNp) showed a negative immune reaction in the cytoplasm of granulosa cells around follicles (Figure 6E).

N.B: Brown coloration considers positive reaction and Blue coloration: negative reaction

Quantitative histomorphometric study (Table 2)

Optical density of PAS staining

Mean optical density of positive PAS staining of control group I was 2.7 ± 0.2 , and that of group II was 1.5 ± 0.16 . Group III and IV mean values of positive PAS staining were 1.96 ± 0.12 and 2.42 ± 0.14 respectively.

Mean area% of TNF- alpha immune staining

TNF-stained sections obtained from group I was 1.6 ± 0.4 . While that of groups II was 16.8 ± 0.7 . Mean area % of immunostaining in group III (metformin) was 9.9 ± 0.5 , and in group IV (SeNp) was 3.4 ± 0.3 .

Mean area% of IL-1 immune staining

Mean area % of immune staining in sections obtained from group I 0.8 ± 0.4 . While that of group II was 7.8 ± 1.2 . Sections from group III (metformin) showed mean area % of immune staining 7.5 ± 1.1 while sections obtained from group IV (SeNp) showed mean area % equal to 4.1 ± 0.3 .

Mean follicular count per field

Mean count of primary, secondary and antral follicles was 10.2 ± 4.6 in group I While in PCOS groups (II) was 5.5 ± 0.6 . In treated groups (III and IV) mean follicular count was raised back to normal values (8.6 ± 0.5 and 9.2 ± 1 respectively).

Biochemical study (Table 3)

Blood biochemical study

The mean values of FSH, LH and total testosterone levels

The mean values (\pm SD) of FSH, LH and total testosterone levels in group I were 6.4 ± 0.52 , 5.5 ± 0.5 , 1.13 ± 0.32 ng/ml respectively. In group II, the values were 3.73 ± 0.87 , 1.49 ± 0.31 , 1.93 ± 0.4 ng/ml respectively. The mean values \pm SD of FSH, LH and total testosterone levels in group III were 4.7 ± 1 , 1.47 ± 0.4 , 1 ± 0.2 ng/ml respectively. While in group IV were 6.6 ± 0.5 , 3.2 ± 0.2 , 0.7 ± 0.2 ng/ml respectively.

The mean values of random blood glucose level

The mean value \pm SD of random BGL in group I was 96 ± 6 . While in group II was 205 ± 10 mg/dl. The mean value \pm SD of random BGL in group III was 98.6 ± 4.1 mg/dl and in group IV was 124 ± 9 mg/dl.

Tissue biochemical study

Superoxide dismutase activity in ovarian tissue of all groups

Ovarian tissue samples from control group (I) showed SOD activity 2.37 ± 0.6 unit/mg and that of PCOS groups (II) were 0.87 ± 0.1 unit/mg. Metformin group showed in SOD activity in ovarian tissue (0.93 ± 0.1 unit/mg). Meanwhile, in SeNp-treated group, there was a significant increase in SOD activity (3.07 ± 0.8 unit/mg) when compared to other groups.

Glutathione peroxidase activity in ovarian tissue of all groups

Ovarian tissue samples from group I was 149.3 ± 12 unit/mg. In PCOS groups (II) GPx activity was 67.4 ± 11.4 unit/mg. Metformin group showed insignificant difference in GPx activity in ovarian tissue (81.3 ± 5.2 unit/mg) in comparison to that of group II. While in SeNp group, there was a significant increase in GPx activity (151.87 ± 16.3 unit/mg) when compared to PCOS groups and metformin group.

Keap1/Nrf2/HO-1 gene expression (Figure 7)

According to Keap1 gene expression, there is a statistically significant increase in PCO group ($6.2 + 0.25$) in comparison to control group ($1 + 0.007$). There was significant decrease in Keap1 gene expression in Metformin received group ($2.8 + 0.21$) and in SeNps received group ($3.3 + 0.1$) in comparison to PCO group.

According to Nrf2 gene expression, there is significant decrease in PCO group ($0.45 + 0.03$) in comparison to control group. In Metformin received group, there is statistically increase in Nrf2 gene expression ($0.74 + 0.04$) while in SeNps received group ($0.87 + 0.02$) in comparison to PCO group.

According to HO-1 gene expression, PCO group shows a statistically significant decrease ($0.28 + 0.04$) compared to control group. While each of Metformin received group and SeNps received group show statistically significant increase ($0.57 + 0.03$ and $0.67 + 0.03$ respectively) compared to PCO group.

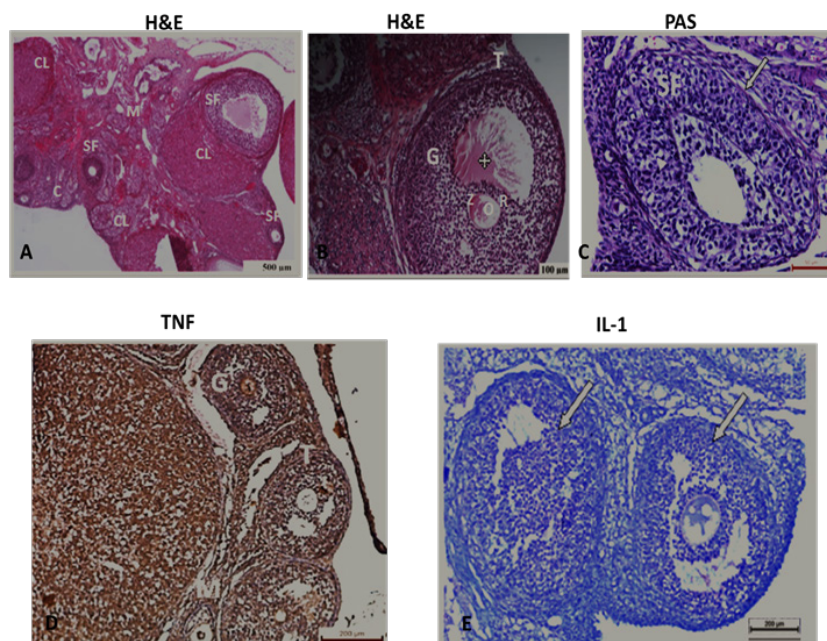


Fig. 3: ovarian stained sections of the control group I A; H&E stained section showed normal histological architecture of the ovary, consisting of outer cortex (C) and inner medulla (M), secondary follicles at different stages of growth (SF) and a corpus luteum (CL). Scale bar: 500 μ m. B: H&E stained section showed the components of a mature Graafian follicle: a central oocyte (O), zona pellucida (Z), corona radiata cells (R), liquor folliculi (+) granulosa cells (G) and theca folliculi cells (T). Scale bar: 100 μ m. C: Ovarian sections revealed moderate positive PAS reaction in the granulosa intercellular spaces and in the granulosa basement membrane (arrow) of a secondary follicle (SF) Scale bar: 50 μ m. D: Ovarian sections showed negative immune reaction for TNF-alpha in the developing granulosa cells (G), theca cells (T) and medullary stroma (M) Scale bar: 200 μ m. E: ovarian sections showed a negative immune reaction to IL-1 antibodies in the granulosa cell layer around follicles (arrows) Scale bar: 200 μ m.

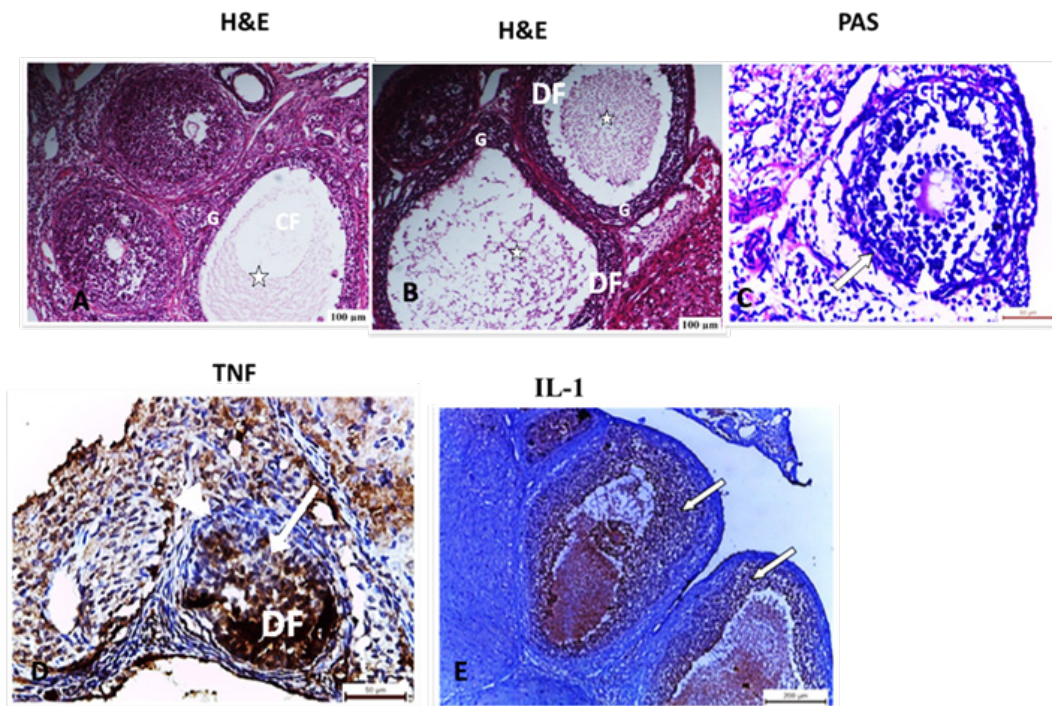


Fig. 4: ovarian stained sections of PCOS group II A: H& E stained section showed a cystic follicle (CF), having a markedly thin granulosa layer (G) and degenerated cell debris in the follicular cavity (asterisk) Scale bar: 100 μ m. B: H& E stained section showed two large degenerating follicles (DF), having thin granulosa layer (G) and cell debris in the lumen of the follicular cavity (asterisk). Scale bar: 100 μ m. C: showed weak positive PAS reaction in a growing follicle (GF) and within the basement membrane (arrow) Scale bar: 50 μ m. D: showed strong positive immune reaction of TNF-alpha in the granulosa cells (arrow) and in the theca cell layer (arrow head) around a degenerating follicle DF (arrow) Scale bar: 50 μ m. E: showed moderate positive immune reaction of IL-1 in the granulosa cell layer around follicles (arrows) Scale bar: 200 μ m.

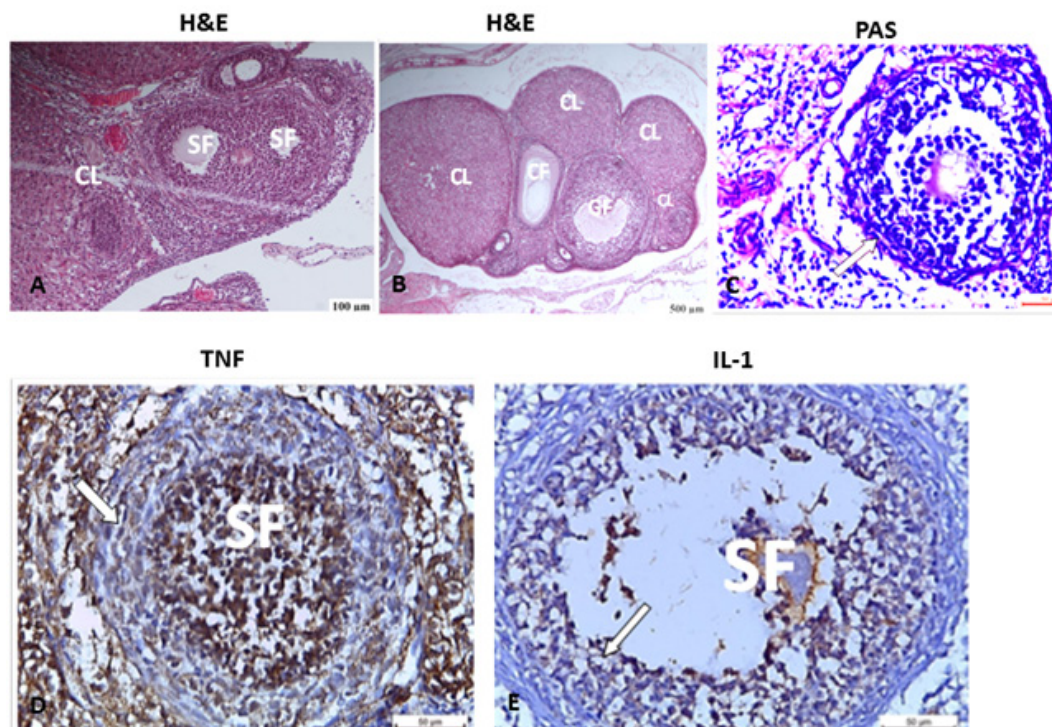


Fig. 5: ovarian stained sections of group III (received metformin) A: H& E stained section elaborated two developing 2ry follicles (SF) with multilaminar granulosa layer and a corpus luteum (CL) Scale bar: 100 μ m. B: Another section showed A cystic follicle (CF), a mature Graafian follicle (GF) and corpus luteum (CL) were also detected. Scale bar: 500 μ m. C: showed strong positive PAS reaction in the granulosa intercellular spaces and basement membrane (arrow) of a Graafian follicle (GF). Scale bar: 50 μ m. D: showed positive immune reaction of TNF- alpha in the granulosa cells (arrow) of a secondary follicle (SF) Scale bar: 50 μ m. E: showed moderate positive immune reaction of IL-1 in the granulosa cell layer around a secondary follicle (arrow). Scale bar: 50 μ m.

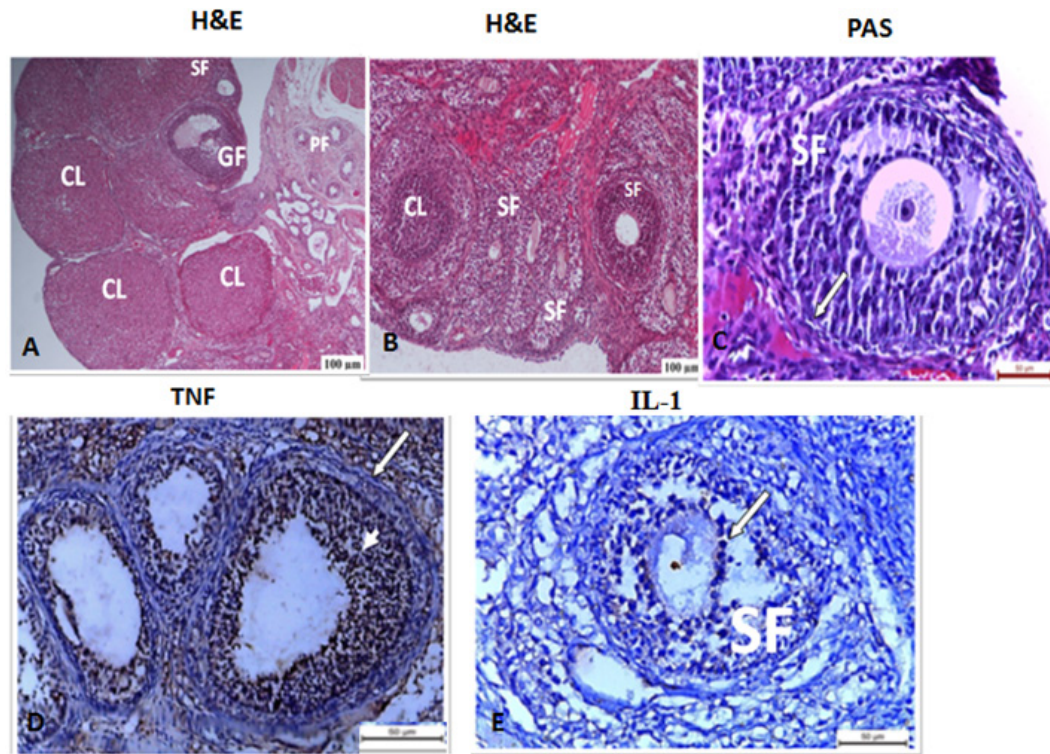


Fig. 6: ovarian sections obtained from group IV (received SNPs) A: H& E stained section showed ovarian follicles in different stages of development were encountered: Primary follicles (PF), a secondary follicle (SF), a mature Graafian follicle (GF) and corpus luteum (CL). Scale bar: 100 μ m. B: H& E stained section showed multiple secondary follicles (SF) with multilaminar granulosa cell layer and a corpus luteum (CL) were detected. Scale bar: 100 μ m. This group displayed an evident ameliorative effect exhibited histological picture nearly similar to its control group. C: showed strong positive PAS reaction in the basement membrane (white arrow) of a secondary follicle (SF). Scale bar: 50 μ m. D: showed negative immune reaction in the granulosa cells (arrow head) and moderate reaction in theca cells around follicles (arrow). Scale bar: 50 μ m. E: showed a negative immune reaction of IL-1 in the granulosa cell layer around a secondary follicle (arrow). Scale bar: 50 μ m.

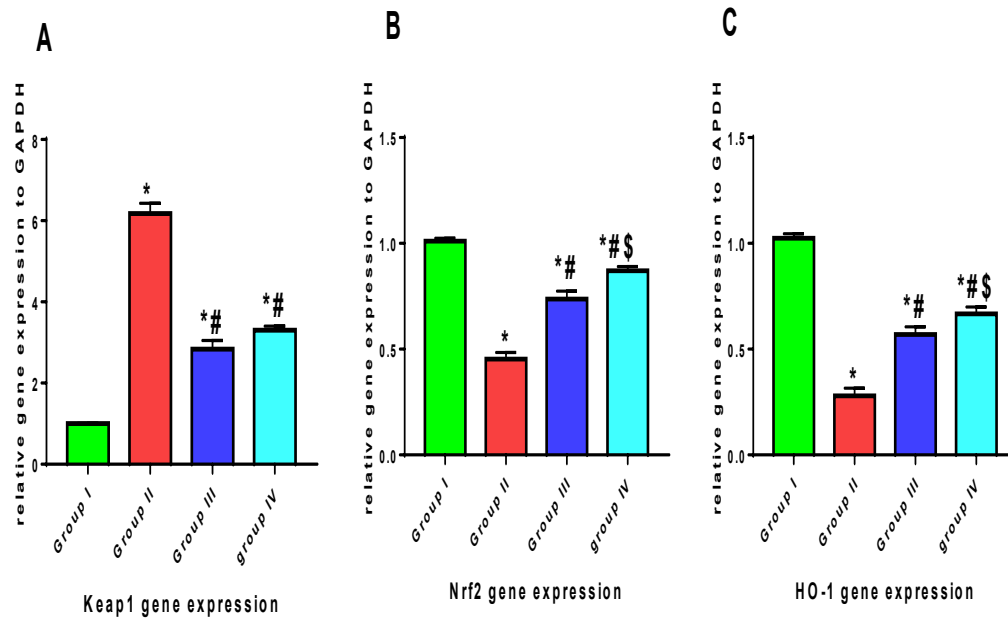


Fig 7: showing gene expression in different study groups
 Data were expressed as Mean \pm SD, p value <0.05 was significant
 (*) Denotes significant difference versus Group I
 (#) Denotes significant difference versus Group II
 (\$) Denotes significant difference versus Group III

Table 2: Showing quantitative histomorphometric study

	Group I	Group II	Group III	Group IV	P value
PAS O.D	2.7 + 0.2	1.5 + 0.168	1.96 + 0.12 *#	2.42 + 0.14 #S	<0.0001
TNF α Mean area %	1.6 + 0.4	16.8 + 0.7 *	9.9 + 0.5*#	3.4 + 0.3 #S	<0.0001
IL-1 Mean area	0.8 + 0.4	7.8 + 1.2 *	* 1.1 + 7.5	4.1 + 0.3*#S	<0.0001
Mean follicular count	10.2 + 4.6	5.5 + 0.6 *	8.6 + 0.5	9.2 + 1	0.03

Data were expressed as Mean \pm SD, p value <0.05 was significant

(*) Denotes significant difference versus Group I

(#)Denotes significant difference versus Group II

(S)Denotes significant difference versus Group III

Table 3: showing mean and SD of the biochemical parameters

	Group I	Group II	Group III	Group IV	P value
FSH	6.4 +0.52	3.73 + 0.87*	4.7 + 1*	6.6 + 0.5#S	<0.0001
LH	5.5 + 0.5	1.49 + 0.31*	1.47 + 0.4*	3.2 + 0.2*#S	<0.0001
Tot. testosterone	1.13 + 0.32	1.93 + 0.4	1 + 0.2 #	0.7 + 0.7 #	0.003
RBS	96 + 6	205 + 10 *	98.6 + 4.1#	124 +9 *#S	<0.0001
SOD	2.3 + 0.6	0.87 + 0.1 *	0.93 + 0.1*	3.07 + 0.8 #S	<0.0001
GxP	149.3 + 12	67.4 + 11.4 *	81.3 + 5.2*	151.87 + 16.3 #S	<0.0001
keap1	1 + 0.007	4.5 + 0.99*	2.2 + 0.28*#	1.9+ 0.16*#	<0.0001
Nrf2	1 + 0.014	0.35 + 0.03*	0.77 + 0.11*#	0.8 + 0.08*#S	0.0001>
HO-1	0.02 + 1	*0.03 + 0.26	0.61 + 0.03*#	0.68 + 0.02*#S	<0.0001

Data were expressed as Mean \pm SD, p value <0.05 was significant

(*) Denotes significant difference versus Group I

(#)Denotes significant difference versus Group II

(S)Denotes significant difference versus Group III

DISCUSSION

Metformin drug has been proved for decades to improve insulin resistance, pregnancy outcomes in PCOS^[12]. The present study aimed to compare the effect of oral metformin in PCOS with a new drug with less side effects.

Selenium salts have delicate toxicity margins^[13], the use of SeNp in the present work reduces the possibility of toxicity, enhances the bioavailability of the substance and improves organ targeting.

PCOS is considered as one of the most controversial entities in gynecological endocrinology. The present study evaluated the histological, immunohistochemical and biochemical changes in the ovarian tissue and systemic circulation in PCOS induced in adult albino rat model using testosterone ethanoate drug. Vaginal smears were taken from the employed rats in the present study, stained with toluidine blue O stain and examined under light microscope, in order to start the experiment in the same phase of the estrous cycle which is characterized by predominance of large cornified epithelial cells arranged in clumps^[14]. The accomplishment of PCOS induction was ensured by serum analysis of random blood glucose level, as well as FSH and LH hormonal assay, at the end of the two weeks. This was considered the zero day of the experiment^[15].

The current study detected elevated serum total testosterone levels in PCOS group II, which was statistically significant increase in comparison with normal control group I. PCOS, being associated with alterations in hypothalamo- hypophyseal- ovarian axis, is usually associated with high androgen levels^[16]. The latter authors advocated that the resultant ovulatory dysfunction is due to androgens acting on androgen receptors (AR) on granulosa cells of developing follicles, causing arrest of follicular growth and cyst formation. The present work supports a causal relationship between high androgen levels and PCOS, in agreement with Razavi *et al.* (2016) who postulated that exposure to elevated androgens in early developmental stages of fetuses of rats could trigger the onset of PCOS in the adult animal.

In the present work, biochemical analysis of serum samples of PCOs group II showed also decreased FSH and increased LH. This is the classic biochemical presentation of PCOS in practice which has also been detected in several previous animal studies^[4,16]. PCOS is usually associated with alterations in the secretion of reproductive hormones particularly an increased LH to FSH ratio^[17]. The latter authors pointed out that growth arrest of small antral follicles is associated with chronic LH stimulation and subsequent dysregulating FSH action on the ovarian follicles due to suppression of FSH receptors on granulosa cells.

In the present work, light microscopic examination of H&E stained sections elaborated histopathologic changes in group II characterized mainly by cyst formation, degenerated and arrested follicles with thickened theca capsule around it, due to hyperplasia of theca interna cells. Histomorphometric analysis of the present study showed a decline in the mean antral follicular count in group II, which was statistically significant in comparison with group I. Similar histopathological changes detected in rats of group II have all been previously reported in several PCOS induced rat models^[5,7,17].

Regarding the cyst formation in PCOS in our results, Rajaei *et al.* (2019) pointed out that it is associated with decreased vascular endothelial growth factor (VEGF) expression^[18]. Another explanation was proposed by Acuna *et al.* (2009) who believed that increased intraovarian sympathetic tone that normally occurs with aging participates in the process of cyst formation in PCOS^[19].

In the present work, ovarian specimens from group I stained with PAS stain showed strong positive reaction in between granulosa cells, in theca cells, in the granulosa basement membranes and in zona pellucida, indicating high content of carbohydrates and glucosaminoglycans (GAGs). In contrast, examination of ovarian sections of group II (PCOS) showed weak PAS reaction within the granulosa and theca cell ground substance. These results appeared close to those of Baravalle *et al.* (2007)^[20]. The latter authors emphasized that carbohydrates and GAGs secreted by granulosa cells play an important role in the differentiation and development of ovarian follicles^[20].

In support with the histological study, histomorphometric analysis of the present work elaborated decreased optical density of PAS staining of specimens of group II, which was statistically significant decreased compared to group I.

In the immunohistochemical study of the present work, TNF-alpha antigen-antibody reaction was detected in ovarian tissue of group II, where most sections showed strong positive anti-TNF alpha staining. the mean area percent of positive immunostaining of TNF-alpha of group II was significantly higher when compared to that of the group I; this has been reported in several previous animal studies^[21,22]. The latter authors pointed out that PCOS is associated with chronic low-grade inflammation and this could explain the elevated circulating inflammatory markers in PCOS, such as TNF-alpha.

Yun *et al.* (2011) stated that TNF-alpha is an inflammatory mediator that is strongly linked to hyperandrogenism, increased insulin resistance and subfertility which are all common findings in PCOS^[23]. In 2014, Thathapudi and colleagues reported that in PCOS patient's serum TNF-alpha is higher compared to control subjects^[21].

In the current work, the mean area percent of IL-1 immunostaining in group II was significantly higher than group I. A biochemical study on women with PCOS aged between 20-40 years, IL-1 levels in their blood was increased compared to control women of the same age^[22]. A more recent study reported elevated IL-1 mRNA in theca, as well as in granulosa cells of the developing follicles in PCOS-rat model^[24]. This is in agreement with Krishnan *et al.* (2020) who detected over-expression of IL-1 in ovarian tissue obtained from dihydrotestosterone-induced PCOS rat model^[25].

Cells exposed to oxidative stress express large levels of Nrf2, HO-1, resulting in increased natural antioxidant levels^[25]. The body boosts Nrf2 expression in an attempt to maintain the functionality of ROS elimination in the early stages of oxidative stress. However, during prolonged oxidative stress that causes cell damage, antioxidant function is harmed much more, resulting in a reduction in Nrf2 expression^[26]. Nrf2 and its downstream targets HO-1 were down regulated while Keap1 was upregulated in our PCO model.

The results of the present work were inconsistent with what Gyftaki and colleagues assumed in 2018 proposed that insulin resistance is the main contributor to oxidative burden in PCOS not the hormonal imbalance itself^[27].

Random blood glucose level (BGL), showed a significant elevation in group II versus group I. PCOS is considered a metabolic-centered syndrome, Several previous biochemical studies on PCOS detected insulin resistance, as well as dyslipidemia; high levels of LDL, VLDL and low levels of HDL^[28,29]. In agreement, Marshall *et al.* (2012) reported that women with PCOS are more likely affected with insulin resistance and compensatory hyperinsulinemia, that appears to be an important factor in maintaining hyperandrogenemia^[30].

In 2018, Eivari *et al.* found that the activity of cytochrome P-450 17-alpha (P-450c 17a) is increased in PCOS; this enzyme is incorporated in the synthesis of pancreatic enzymes and insulin production, which explains in another way hyperinsulinemia in PCOS^[31].

In the present study, the role of metformin drug was evaluated in PCOS; its effect on histological, immunohistochemical and biochemical parameters was compared with the newly emerging therapy, selenium. Insulin sensitizer has a pharmaceutical role in PCOS. Hirschberg (2009) deduced that PCOS is associated with accumulation of abdominal fat, obesity and insulin resistance; moreover it is strongly linked to impaired glucose tolerance (IGT), type 2 diabetes and dyslipidemia^[32].

In the present work, regarding metformin group (III), normal histological architecture of the ovary was denoted in several ovarian sections obtained from rats of this group and regular ovulation was restored. Previous literature that implied metformin drug for PCOS treatment reported similar histological findings^[33]. Comparing to

group IV, that received selenium nanoparticles for 21 days via intraperitoneal injection, H&E stained sections showed restored appearance of the normal histological architecture of the ovary, improvement in the number of normal developing antral follicles, with the development of mature Graafian follicles and corpora lutea in most sections. These results are consistent with previous studies that used selenium salts for PCOS^[6,7].

Histomorphometric analysis of the present work showed increased mean number of follicles in group III, with a statistically significant increment in comparison with group II. This denotes that metformin drug was able to regain normal follicular count in most ovaries. The mean follicular count of group IV was significantly higher compared to groups II and III. Atef *et al.* (2019) found a significant reduction of both serum and ovarian levels of selenium in rat model of PCOS^[5].

Furthermore, the mean optical density of PAS stained ovarian sections of group III was significantly higher than that in group II, pointing out a restoration of normal extracellular and basement membrane carbohydrates and GAGs secreted by normally functioning granulosa cells. Previous clinical studies showed an increased incidence of ovulation in women with PCOS who take oral metformin^[32]. Furthermore, Eivari *et al.* (2018) hypothesized that metformin can decrease plasma levels of androgens, LH and insulin-like growth factor 1 (IGF-1) by reducing the level of insulin, which in turn, reduces the action of P-450c17a.

PAS staining of group IV showed a strong positive reaction in between granulosa and theca cell layers. The optical density of PAS staining was significantly higher in group IV compared to group II and III, denoting regained normal functioning of granulosa cells. This advocated to the role of selenium deficiency and exaggerated oxidative stress in the pathogenesis of PCOS as deduced by Rezvanfar *et al.* (2014) and support the role of selenium supplementation in restoring normal granulosa cell functioning^[34].

Regarding the immunohistochemical findings in the present study, in group III, expression of TNF-alpha was weak to moderate in most ovaries, while IL-1 cytokine showed overexpression in nearly all examined sections. The mean area percent of immunoreactivity of TNF-alpha in group III was quite similar to group II, with no significant difference between them. Also the mean area percent of immunostaining of IL-1 stained sections, showed no significant difference between group II and III. This denotes that metformin did not have a role in improving TNF-alpha or IL-1 increased levels in PCOS.

Regarding the group IV of the present study, most sections showed weak expression of both TNF- alpha and IL-1 antibodies. Statistical analysis elaborated a significant decrease in the mean area percent of immunoreactivity of TNF alpha and IL-1 in group IV versus group II. This is consistent with what was deduced by Ghowsi *et al.* (2017),

who found decreased activity of TNF-alpha and IL-1 using sodium selenite^[14]. Razavi *et al.* (2016) pointed out that proteins that include selenocysteine in their polypeptide chain are defined as selenoproteins^[13]. Ramoutar *et al.* (2010) outlined that selenoproteins have antiinflammatory, antiviral and anticancer properties, thus protects against several cardiovascular and metabolic disorders, including PCOS^[35].

Comparing the immunohistochemical results of group III with group IV in the present study, the mean area percent of TNF-alpha and IL-1 immunostaining were significantly higher in the granulosa cells of group III that received oral metformin. This finding emphasizes better effective role of SeNp in improving inflammatory related conditions. In 2016, Razavi *et al.* reported that in women aged 18-40 years with PCOS, who received 200 microgram/day Se for eight weeks, pregnancy rate increased, hs-CRP and plasma MDA levels decreased, while insulin level and lipid profile improved^[13].

In the present work, biochemical analysis of group III, showed that serum level of LH was lowered, while that of FSH was increased in rats that received metformin. Processing of these findings showed that LH decrease in group III was statistically significant compared to group II. This is consistent with several previous studies that reported that metformin restores gonadotropins level back to normal in PCOS^[7,36].

In the present work, total testosterone level in metformin group was significantly lowered, compared to PCOS and recovery groups. Rezvanfar *et al.* (2014) performed a randomized placebo-controlled double-blind study on adolescent girls with PCOS, which showed that metformin therapy causes a significant decline in mean serum testosterone level^[34]. However other studies suggested that there is a direct effect of metformin on androgen production at the ovarian level, Maged *et al.* (2015) reported that *in vitro* production of androgens by theca cells can be reduced by adding metformin^[37].

Hormonal assessment of blood samples obtained from group IV, showed decreased total testosterone level, increased FSH and decreased LH levels^[37]. Previous literature pointed out that Se can restore normal hormonal levels in PCOS^[5,38]. However, Hosseinzadehet *et al.* (2016) and Razavi *et al.* (2016) claimed that Se intake did not affect hormonal profiles of PCOS women. The mechanism by which selenium affects hormonal blood levels is still a matter of debate^[39,11]. Atef *et al.* (2019) attributed that to its combined effect in improving oxidative stress enzymes and regulating serum androgen level and thus restoring normal physiologic functioning of hepatocytes^[5].

In the present work, SeNps administration lowered the high level of blood glucose. BGL was significantly lower in group IV versus group II and III. Different studies show controversial results on the effect of selenium on BGL, improved glycemic control with Se might result from its effect on increasing genetic expression of peroxisome

proliferator activated receptor gamma (PPAR- gamma) and glucose transporter 1 (GLUT-1)^[39].

In the current work, group IV showed increased GPx and SOD levels, significantly higher in comparison with PCOS and metformin groups. Similar findings were reported by previous studies^[11]. Modaress *et al.* (2018) pointed out that women with PCOS have lower level of plasma Se compared to healthy women^[40].

In the current study, Keap1 reduced in both group III and IV, but it did not return to normal levels. In compared to the PCO group, there is a significant reduction. The difference between the two groups is not statistically significant. In compared to the PCO group, the levels of nrf2 and its substrate HO-1 have significantly increased. There is also a significant difference between metformin groups III and IV. The efficacy of metformin and selenium nanoparticles in competing oxidative stress via gene expression was demonstrated in our work. These results agreed with Du *et al*, 2020 who proved metformin therapy improved the obesity phenotype, improved metabolic abnormalities^[28].

Co-treatment SeNPs and Metformin prevented diabetic rats from developing testicular oxidative injury through mechanisms involving oxidative stress, inflammation, hormonal imbalance, enhancement of steroidogenic enzymes/proteins, and regulation of the Nrf2 pathway, as well as improved sperm functional parameters^[41]. The anti-androgenic impact of Se and SeNPs in the treatment of PCOS was proven in study done by Butt *et al* 2020. Selenium and selenium NPs alleviated ovarian dysfunction, decreased the number of ovarian cysts, increased the balance between antioxidant enzymes and reactive oxygen species (ROS), and restored a normal lipid profile. Se and SeNP demonstrated protective potentials in female rats, improving hormonal concentrations of testosterone, estradiol, and progesterone. Se and SeNP also performed a major impact in lowering hyperglycemia, implying that they could be used as a treatment for the clinical and biochemical symptoms of polycystic ovarian syndrome^[6].

CONCLUSION

The results of the present study might draw attention to the effective and promising role of SeNP in the treatment of PCOS. Its effect is not only comparable to that of metformin drug in histological follicular restoration, hormonal and blood glucose level regulation, but even superior to it regarding immunological and biochemical improvement.

CONFLICT OF INTERESTS

There are no conflicts of interest.

REFERENCES

1. Witchel SF, Burghard AC, Tao RH, Oberfield SE. The diagnosis and treatment of PCOS in adolescents: an update. *Current Opinion in Pediatrics*. 2019 Aug 1;31(4):562-9
2. Alexiou E, Hatzigelaki E, Pergialiotis V, Chrelias C, Kassanos D, Siristatidis C, Kyrkou G, Kreatsa M, and Trakakis E. Hyperandrogenemia in women with polycystic ovary syndrome: prevalence, characteristics and association with body mass index. *Hormone molecular biology and clinical investigation*. 2017 Mar 1; 29(3):105-11.
3. Hajizadeh-Sharafabad F, Moludi J, Tutunchi H, Taheri E, Izadi A, Maleki V. Selenium and Polycystic Ovary Syndrome; Current Knowledge and Future Directions: A Systematic Review. *Horm Metab Res*. 2019; 51(5):279-287. Doi: 10.1055/a-0890-6823.
4. Jamilian M, Razavi M, Fakhrie Kashan Z, Ghandi Y, Bagherian T, Asemi Z. Metabolic response to selenium supplementation in women with polycystic ovary syndrome: a randomized, double-blind, placebo-controlled trial. *Clinical endocrinology*. 2015 Jun; 82(6):885-91.
5. Atef MM, Abd-Ellatif RN, Emam MN, Amer AI, Hafez YM. Therapeutic potential of sodium selenite in letrozole induced polycystic ovary syndrome rat model: Targeting mitochondrial approach (selenium in PCOS). *Archives of biochemistry and biophysics*. 2019 Aug 15; 671:245-54.
6. Butt MA, Ullah A, Kiyani MM, Jahan S. Ameliorative effects of selenium nanoparticles on letrozole induced polycystic ovarian syndrome in adult rats. *International Journal of Biomedical Nanoscience and Nanotechnology*. 2020;4(1-2):49-69.
7. Jamilian M, Mansury S, Bahmani F, Heidar Z, Amirani E, Asemi Z. The effects of probiotic and selenium co-supplementation on parameters of mental health, hormonal profiles, and biomarkers of inflammation and oxidative stress in women with polycystic ovary syndrome. *Journal of ovarian research*. 2018 Dec; 11(1):1-7.
8. Paixão L, Ramos RB, Lavarda A, Morsh DM, Spritzer PM. Animal models of hyperandrogenism and ovarian morphology changes as features of polycystic ovary syndrome: a systematic review. *Reproductive Biology and Endocrinology*. 2017 Dec; 15(1):1-1.
9. Bancroft JD and Gamble M (2008): *Theory and practice of histological techniques*. 6th edition, Elsevier health science. 126-127.
10. Ramos-Vara JA, Kiupel M, Baszler T, Bliven L, Brodersen B, Chelack B, West K, Czub S, Del Piero F, Dial S, Ehrhart EJ, Graham T, Manning L, Paulsen D and Valli VE (2008). Suggested guidelines for immunohistochemical techniques in veterinary diagnostic laboratories. *J Vet Diagn Invest.*, 20: 393–413.

11. Choi JH, Jang M, Kim EJ, Lee MJ, Park KS, Kim SH, In JG, Kwak YS, Park DH, Cho SS, Nah SY. Korean Red Ginseng alleviates dehydroepiandrosterone-induced polycystic ovarian syndrome in rats via its antiinflammatory and antioxidant activities. *Journal of ginseng research*. 2020 Nov 1; 44(6):790-8.
12. Di Pietro M, Parborell F, Irusta G, Pascuali N, Bas D, Bianchi MS, Tesone M, Abramovich D. Metformin regulates ovarian angiogenesis and follicular development in a female polycystic ovary syndrome rat model. *Endocrinology*. 2015 Apr 1; 156(4):1453-63.
13. Razavi M, Jamilian M, Kashan ZF, Heidar Z, Mohseni M, Ghandi Y, Bagherian T, Asemi Z. Selenium supplementation and the effects on reproductive outcomes, biomarkers of inflammation, and oxidative stress in women with polycystic ovary syndrome. *Hormone and Metabolic Research*. 2016 Jun; 48(03):185-90.
14. Matsumoto Y, Miwa S, Zhang Y, Hiroshima Y, Yano S, Uehara F, Yamamoto M, Toneri M, Bouvet M, Matsubara H, Hoffman RM. Efficacy of tumor-targeting Salmonella typhimurium A1-R on nude mouse models of metastatic and disseminated human ovarian cancer. *Journal of Cellular Biochemistry*. 2014 Nov; 115(11):1996-2003.
15. Razavi M, Jamilian M, Kashan ZF, Heidar Z, Mohseni M, Ghandi Y, Bagherian T, Asemi Z. Selenium supplementation and the effects on reproductive outcomes, biomarkers of inflammation, and oxidative stress in women with polycystic ovary syndrome. *Hormone and Metabolic Research*. 2016 Jun; 48(03):185-90.
16. Ghowsi M, Khazali H, Sisakhtnezhad S. The effect of resveratrol on oxidative stress in the liver and serum of a rat model of polycystic ovary syndrome: An experimental study. *International Journal of Reproductive Biomedicine*. 2018 Mar; 16(3):149.
17. Teixeira CP, Florencio-Silva R, Sasso GR, Carbonel AA, Simões RS, Simões MJ. Soy isoflavones protect against oxidative stress and diminish apoptosis in ovary of middle-aged female rats. *Gynecological Endocrinology*. 2019 Jul 3; 35(7):586-90.
18. Rajaei S, Alihemmati A, Abedelahi A. Antioxidant effect of genistein on ovarian tissue morphology, oxidant and antioxidant activity in rats with induced polycystic ovary syndrome. *International Journal of Reproductive Biomedicine*. 2019 Jan; 17(1):11.
19. Acuña E, Fornes R, Fernandois D, Garrido MP, Greiner M, Lara HE, Paredes AH. Increases in norepinephrine release and ovarian cyst formation during ageing in the rat. *Reproductive Biology and Endocrinology*. 2009 Dec; 7(1):1-3.
20. Baravalle C, Salvetti NR, Mira GA, Lorente JA, Ortega HH. The role of ACTH in the pathogenesis of Polycystic Ovarian Syndrome in the rat: hormonal profiles and ovarian morphology. *Physiological Research*. 2007, 56(1).
21. Thathapudi S, Kodati V, Erukkambattu J, Katragadda A, Addepally U, Hasan Q. Tumor necrosis factor-alpha and polycystic ovarian syndrome: a clinical, biochemical, and molecular genetic study. *Genetic Testing and Molecular Biomarkers*. 2014 Sep 1; 18(9):605-9.
22. Abuelezz NZ, Shabana ME, Abdel-Mageed HM, Rashed L, Morcos GN. Nanocurcumin alleviates insulin resistance and pancreatic deficits in polycystic ovary syndrome rats: Insights on PI3K/AkT/mTOR and TNF- α modulation. *Life sciences*. 2020 Sep 1; 256:118003.
23. Yun JH, Choi JW, Lee KJ, Shin JS, Baek KH. The promoter-1031 (T/C) polymorphism in tumor necrosis factor-alpha associated with polycystic ovary syndrome. *Reproductive Biology and Endocrinology*. 2011 Dec; 9(1):1-6.
24. Zangeneh FZ, Naghizadeh MM, Masoumi M. Polycystic ovary syndrome and circulating inflammatory markers. *International Journal of Reproductive Biomedicine*. 2017 Jun; 15(6):375.
25. Krishnan A, Muthusami S, Periyasamy L, Stanley JA, Gopalakrishnan V, Ramachandran I. Effect of DHT-induced hyperandrogenism on the pro-inflammatory cytokines in a rat model of polycystic ovary morphology. *Medicina*. 2020 Mar; 56(3):100.
26. Popovic M, Sartorius G, Christ-Crain M. Chronic low-grade inflammation in polycystic ovary syndrome: is there a (patho)-physiological role for interleukin-1? *In Seminars in immunopathology 2019 Jul (Vol. 41, No. 4, pp. 447-459)*. Springer Berlin Heidelberg.
27. Gyftaki R, Gougoura S, Kalogeris N, Loi V, Koukoulis G, Vryonidou A. Oxidative stress markers in women with polycystic ovary syndrome without insulin resistance. *In Endocrine Abstracts 2018 May 8 (Vol. 56)*. Bioscientifica.
28. Du L, Wang L, Wang B, Wang J, Hao M, Chen YB, Li XZ, Li Y, Jiang YF, Li CC, Yang H. A novel compound AB38b attenuates oxidative stress and ECM protein accumulation in kidneys of diabetic mice through modulation of Keap1/Nrf2 signaling. *Acta Pharmacologica Sinica*. 2020 Mar; 41(3):358-72.
29. Coskun A, Arikan T, Kilinc M, Arikan DC, Ekerbiçer HÇ. Plasma selenium levels in Turkish women with polycystic ovary syndrome. *European Journal of Obstetrics & Gynecology and Reproductive Biology*. 2013 Jun 1; 168(2):183

30. Marshall JC, Dunaif A. Should all women with PCOS be treated for insulin resistance?. *Fertility and sterility*. 2012 Jan 1; 97(1):18-22.
31. Abtahi-Eivari S, Moghimian M, Soltani M, Shoorei H, Asghari R, Hajizadeh H *et al*. The Effect of Galega officinalis on Hormonal and Metabolic Profile in a Rat Model of Polycystic Ovary Syndrome. *International Journal of Women's Health and Reproduction Sciences*. 2018; 6(3):276-282.
32. Khodaeifar F, Fazljou SM, Khaki A, Torbati M, Madarek EO, Khaki AA, Shokoohi M, Dalili AH. Investigating the role of hydroalcoholic extract of *Apium graveolens* and *Cinnamon zeylanicum* on metabolically change and ovarian oxidative injury in a rat model of polycystic ovary syndrome. *Int J Womens Health Reprod Sci*. 2019 Jan 1; 7(1):92-8.
33. Teede H, Misso M, Tassone EC, Dewailly D, Ng EH, Azziz R, Norman RJ, Andersen M, Franks S, Hoeger K, Hutchison S. Anti-Müllerian hormone in PCOS: a review informing international guidelines. *Trends in Endocrinology & Metabolism*. 2019 Jul 1; 30(7):467-78.
34. Rezvafar MA, Saeedi S, Mansoori P, Saadat S, Goosheh M, Shojaei Saadi HA, Baeri M, Abdollahi M. Dual targeting of TNF- α and free radical toxic stress as a promising strategy to manage experimental polycystic ovary. *Pharmaceutical Biology*. 2014 Jan 2; 54(1):80-90.
35. Ramoutar RR, Brumaghim JL. Antioxidant and anticancer properties and mechanisms of inorganic selenium, oxo-sulfur, and oxo-selenium compounds. *Cell biochemistry and biophysics*. 2010 Sep; 58(1):1-23.
36. Lashen H. Role of metformin in the management of polycystic ovary syndrome. *Therapeutic advances in endocrinology and metabolism*. 2010 Aug; 1(3):117-28.
37. Maged A.M., Elsayah H, Abdelhafez A, Bakry A, Mostafa WA. The adjuvant effect of metformin and N-acetylcysteine to clomiphene citrate in induction of ovulation in patients with Polycystic Ovary Syndrome. *Gynecological endocrinology*. 2015 Aug 3;31(8):635-8.
38. Horakova O, Kroupova P, Bardova K, Buresova J, Janovska P, Kopecky J, and Rossmeisl M. Metformin acutely lower blood glucose levels by inhibition of intestinal glucose transport. *Scientific reports*. 2019 Apr 16;9(1):1
39. Hosseinzadeh FM, Hosseinzadeh-Attar MJ, Yekaninejad MS, Rashidi B. Effects of selenium supplementation on glucose homeostasis and free androgen index in women with polycystic ovary syndrome: a randomized, double blinded, placebo controlled clinical trial. *Journal of Trace Elements in Medicine and Biology*. 2016 Mar 1; 34:56-61.
40. Zadeh Modarres S, Heidar Z, Foroozanfard F, Rahmati Z, Aghadavod E, Asemi Z. The effects of selenium supplementation on gene expression related to insulin and lipid in infertile polycystic ovary syndrome women candidate for *in vitro* fertilization: A randomized, double-blind, placebo-controlled trial. *Biological trace element research*. 2018 Jun; 183(2):218-25.
41. Ebokaiwe AP, Obeten KE, Okori SO, David EE, Olusanya O, Chukwu CJ, Okoro N, Ehiri RC. Co-administration of selenium nanoparticles and metformin abrogate testicular oxidative injury by suppressing redox imbalance, augmenting sperm quality and Nrf2 protein expression in streptozotocin-induced diabetic rats. *Biological Trace Element Research*. 2020 Dec; 198(2):544-56.

المخلص العربي

دور جزيئات النانوسيلينيوم مقارنة بعقار الميتفورمين في متلازمة تكيس المبايض المستحثة في الفأر الابيض البالغ: دراسة هيستولوجية و مناعية هيستوكيميائية وكيميائية حيوية

غادة نادى عويس^١، محمد عماد الدين إبراهيم^١، محمد حافظ شعبان^١، اسماء سيد محمد السيد شاهين، مروي محمد عبد الجواد^٢

^١قسم التشريح وعلم الأجنة، ^٢قسم الكيمياء الحيوية الطبية، كلية الطب، جامعه القاهرة

مقدمه: متلازمة تكيس المبايض هي خلل وظيفي في المبايض، تتميز بشكل رئيسي بفرط الأندروجين وحالة الإجهاد التأكسدي. عقار الميتفورمين هو علاج فموي تقليدي لمتلازمة تكيس المبايض. لذلك يهدف هذا العمل إلى توضيح الدور العلاجي لجزيئات النانو سيلينيوم في المتلازمة ومقارنتها مع علاج الميتفورمين، في متلازمة تكيس المبايض المستحثة في الفئران البيضاء البالغة.

الهدف من البحث: تم تقسيم أربعون فأراً ابيضاً بالغاً إلى: اربعة مجموعات متساويه المجموعة الأولى (تحكم طبيعي)، المجموعة الثانية (متلازمة تكيس المبايض) ، المجموعة الثالثة (الميتفورمين) تلقت الميتفورمين عن طريق الفم لمدة ٢١ يوماً ، والمجموعة الرابعة (السيلينيوم) تلقت جزيئات النانو سيلينيوم لمدة ٢١ يوماً عن طريق الحقن داخل الغشاء البريتوني.

المواد والطرق: تم الحصول على عينات دم و عينات من نسيج المبيض في الفئران المستخدمة في التجربة. عينات المبيض تم تحضيرها للدراسة المجهرية الضوئية ، وصبغات الهيستوكيميائية المناعية باستخدام الأجسام المضادة لـ TNF-alpha و IL-1، وتم إجراء دراسة كيميائية حيوية لقياس مستوى الإنزيمات GPx و SOD في نسيج المبيض، واختبارات الدم الهرمونية ، والتقييم المورفوميترى والتحليلات الإحصائية.

النتائج: أظهرت الدراسة المجهرية الضوئية أن كلا من عقار الميتفورمين و جزيئات النانو سيلينيوم يحسنان البنية النسيجية للمبيض المصاب ، ويستعيدان النمو الطبيعي لبصيلات المبيض و قدرتها على التبويض المنتظم . وقد أثبتت الدراسة زيادة ذات دلالة احصائية في متوسط عدد البويضات الطبيعية في مجموعات الميتفورمين و السيلينيوم. كما قام الميتفورمين و النانو سيلينيوم بتحسين مستويات الدم الهرمونية لهرمونات FSH و LH و Testosterone ، و أظهرت مجموعة السيلينيوم تحسن ذات دلالة احصائية في تحسين مستوى هرمون ال LH مقارنة بمجموعة الميتفورمين. عزز النانوسيلينيوم نشاط إنزيمات التأكسد GPx و SOD في نسيج المبيض و رفع معدلاتهم مقارنة بمجموعة متلازمة تكيس المبايض و مجموعة التعافى و مجموعة الميتفورمين ، وقلل من وسطاء التهابات الأنسجة TNF-alpha و IL-1 في أنسجة المبيض التي تم فحصها مقارنة بباقي المجموعات .

الإستنتاج: على الرغم من أن عقار الميتفورمين و جزيئات النانوسيلينيوم لا يختلفان عن بعضهما البعض في استعادة القدرة الطبيعية للمبيض المصاب على التبويض المنتظم و ضبط مستويات الدم الهرمونية ، وجد أن النانوسيلينيوم أفضل من الميتفورمين في تحسين حالة إنزيمات الأكسدة بخلايا المبيض وفي خفض نشاط ووسطاء التهابات الأنسجة المرتفعة في متلازمة تكيس المبايض المستحثة في الفئران.