

Effect of Tramadol and Vardenafil Alone and in Combination on Adult Male Mice Reproductive Performance and Fertility

Original Article *Marwa Samir Abdel-Salam¹, Abdel-Rahman Tawfik¹, Abdel-Rahman Sayed Sultan² and Heba Ali Abd El Rahman¹*

Faculty of Science, Department of Zoology, ¹Cairo University, Giza, ²El Azhar University, Assuit, Egypt

ABSTRACT

Introduction: Tramadol is one of the most common analgesic drugs in chronic pain treatment. Their mechanism of action is through the inhibition of the noradrenaline and serotonin (5-HT) transmission reuptake. Vardenafil is used to treat male sexual function problems like erectile dysfunction.

Objective: The present work aimed to evaluate the biochemical and testicular histopathological changes induced by tramadol and/or vardenafil administration in adult male Swiss mice and investigate the associated impact of tramadol and vardenafil on fertility and reproductive performance.

Materials and Methods: 24 mature male Swiss mice with a body weight of 30-35 g have been divided into 4 groups. (G1) control, (G2) injected i.p with 4.16 mg/kg of tramadol, (G3) injected i.p with 46.8 mg/kg of vardenafil, and (G4) treated with tramadol followed with vardenafil. Sperm samples were collected from cauda epididymis, semen profile examination and abnormalities were recorded. Hormonal analysis, oxidative stress biomarkers, and histopathological studies have been done.

Results: The present study revealed that tramadol and vardenafil synergistically did not altered body weight of mice and not caused change of reproductive organs' weight. Administration of tramadol and vardenafil revealed reduction in mating index and fetal weight. The results indicated that tramadol and vardenafil have a significantly harmful impact on sperm quality, boosted morphological abnormalities, decreased concentration of reproductive hormones, induced testicular histopathological changes, and affected spermatogenesis cycle, decreasing number of spermatogonia and spermatocytes, altered antioxidants levels and raised MDA activity.

Conclusion: Intake of tramadol and vardenafil should be for a short period and necessary because of their serious harmful effects on reproductive performance and fertility.

Received: 20 July 2022, **Accepted:** 08 August 2022

Key Words: Mice, reproductive performance, spermatogenesis, tramadol, vardenafil.

Corresponding Author: Heba Ali Abd El-Rahman, PhD, Faculty of Science, Department of Zoology, Cairo University, Giza, Egypt, **Tel.:** +20 11 2707 0059, **E-mail:** hebaabdelrahmana15@cu.edu.eg

ISSN: 1110-0559, Vol. 46, No. 4

INTRODUCTION

It has been suggested that exposure to environmental toxins may contribute to male reproductive and fertility problems. The painkiller tramadol is commonly used to treat persistent neuropathic pain, cancer pain, and surgical distress. Tramadol is a ligand for opioid receptors. It blocks the reuptake of serotonin and norepinephrine to increase the inhibitory action on spinal cord pain transmission Grond and Sablotzki^[1].

This opioid drug's chronic use has been linked to addiction. Although tramadol's therapeutic properties, continuous dosing may cause hazardous intermediates to build up, raise the chance of pharmacokinetic complications, or reduce the drug's clearance Salah *et al.*^[2]. Hepatotoxicity and nephrotoxicity as harmful impacts of this opioid medication by Adelakun *et al.*^[3].

A 5-phosphodiesterase (PDE5) inhibitor termed Vardenafil (VRD) has been one of the medications used to treat erectile dysfunction. Regarding sexual stimulation,

VRD opens blood vessels, increases circulation, and suppresses an enzyme in the smooth muscle cells lining the blood arteries nourishing the corpus cavernosum of the penis Li *et al.*^[4].

Sildenafil (Viagra), a medication used to treat erectile dysfunction in males, was found to cause tubular and interstitial histopathological changes of the seminiferous tubules as well as tubular deterioration, which could ultimately result in the halt of spermatogenesis, according to earlier research El kerdasy and Mohamed^[5].

AIM OF THE WORK

While much is known about the development of the male reproductive system and many causes of specific disorders, the research about the mechanisms of action for certain pathologies is still largely unknown and needs support through greater levels of research. The present work aimed to evaluate the biochemical and testicular histopathological changes induced by tramadol and/or vardenafil administration in male Swiss mice.

MATERIALS AND METHODS

Animals

The National Organization for Drug Control and Research in Egypt provided adult male Swiss mice with body weights ranging from 30 to 35 g for the current study. The animals were housed in conventional mouse cages in a room for humidity and temperature control. The animals had a consistent schedule of 12 hours of light and 12 hours of darkness. The animals were fed a basic diet of rodents and had free access to water.

The institutional animal care and use committee's (IACUC's) guidelines for handling laboratory animals during experimental work were followed, and approval number CU/I/F/58/18 was used as a reference.

Chemical

Tablets of tramadol or amadol. Each of the tramadol capsules that are sold commercially includes 50 mg of tramadol hydrochloride (Amadol, manufactured by ADWIA Co. S.A.E., 10th of Ramadan City, Egypt). Tramadol treatment dosages were equivalent to human effective therapeutic levels.

Vardenafil 20 mg manufactured by Eva pharm company, obtained from Elezaby pharmacy in Egypt. The dose was chosen to be like the regular dose for managing erectile dysfunction (ED).

Design of the study

Six fully grown males from each of the twenty-four mice were divided into the following categories:

Group 1 (control): Mice received 0.1 ml of sterile, distilled water intraperitoneally (i.p.) every day for 30 days.

Group 2: For 30 days, 4.16 mg/kg of tramadol was injected intraperitoneally (i.p.) into mice. According to Nair and Jacob^[6], the recommended therapeutic dosage was calculated.

Group 3: For 30 days, mice received daily intraperitoneal injections of 46.8 mg/kg of body weight of vardenafil.

Group 4: For 30 days, mice received daily injections of 46.8 mg of vardenafil and 4.16 mg of tramadol intraperitoneally (i.p.).

Mating index

At the end of the experiment, the treated animals shared a living area in a 1:1 ratio with normal, healthful untreated females for two subsequent estrus cycles. Females were regularly checked for the presence of a copulatory plug in the vagina to confirm mating. The day that a seminal plug was observed was referred to as gestational zero-day.

Fetuses' collection

Fetuses were removed from their mothers' wombs

through cervical dislocation on the 20th day of pregnancy. They were weighed and examined for obvious abnormalities according to Oderinde *et al.*^[7].

Blood samples were drawn for the hormones (Testosterone, LH and FSH) testing in a sterilized test tube after the male mice were euthanized and dissected according to protocols and ethical guidelines. Blood was centrifuged for 15 minutes at 3000 rpm to get the serum. The sera were kept at - 20°C for subsequent biochemical research at Comparative Anatomy and Embryology lab, Zoology Department, Faculty of Science, Cairo University.

The body weights were measured on the day of the scarifying. The cauda epididymis, seminal vesicles, and testes were separated and weighed. For biochemical research, the left testes were frozen at - 20°C, while the right ones were kept in a 10 percent neutral formalin solution for histology research.

Sperm analysis

The left epididymis was detached and was placed in 5 mL of phosphate-buffered saline at 7.2 pH (PBS). It was then kept at 37 degrees Celsius in the incubator for 20 minutes.

Sperm Count

One drop of sperm suspension was applied to a hemocytometer using the Lowe and Teffrey protocol^[8]. The count was carried out five times for each sample to minimize the error.

Morphological abnormalities

Hematoxylin-Eosin and Nigrosine stain were applied to one drop of the sperm suspension for morphology. One drop of this combination was added to a clean slide and examined under a light microscope, according to Goyal *et al.*^[9].

Hormonal analysis

The concentrations of testosterone (T), follicle-stimulating hormone (FSH), and luteinizing hormone (LH) were measured using ELISA kits purchased from (Sunlong biotech co, LTD).

Oxidative stress investigation

Testicular biopsy samples from various groups of testicles were kept in storage at -20° C for the oxidative stress inquiry. In 10 mmol/L phosphate buffer saline (PBS) at pH 7.4, pieces of each tissue were weighed and homogenized as 10% (W/V) solutions. The homogenates were centrifuged, and the filtrates were used to estimate glutathione (GSH) according to the method of Beutler^[10] catalase (CAT) according to Aebi^[11], and malondialdehyde (MDA) according to the method of Ohkawa^[12] utilizing reagent products purchased from Bio Diagnostic (Egypt).

Histopathology assessment

Right testes were removed and maintained in Bouin solution for 24 hours. After being replaced by xylene and embedded in paraffin, different alcohol concentrations were fixed. Five-micron sections of each testis were cut out, stained with hematoxylin-eosin, viewed under a light microscope, and photographed with a digital camera.

Morphometric evaluation

Up to 30 seminiferous tubule sections from each group were almost spherical. Image J software program calculated the tubular diameter, spermatogonia, and spermatocyte counts at a 400X magnification.

Statistical evaluation

The statistical analysis was performed using the computer program SPSS 17.0 (statistical package for social science). The differences between groups were ascertained using one-way analysis of variance (ANOVA) and Tukey's multiple comparison post hoc analysis. Means and standard errors were used to express the data. $P < 0.05$ was used to determine whether the difference between the groups was statistically significant.

RESULTS

Mating outcome

The intake of tramadol or vardenafil or both drugs simultaneously showed a significant reduction in the fetal weight compared to the control (Table 1, Figure 1). The intake of tramadol and vardenafil showed significant changes compared to tramadol or vardenafil (Table 1). Tramadol and vardenafil intake reduced mating index percent during two successive estrus cycles (Table 1).

Reproductive organs weight

The administration of tramadol (4.16 mg/kg) or/and vardenafil (46.8 mg/kg) daily for 30 days showed non-significant changes in the weight of testis and epididymis compared to the control (Table 2). The left seminal vesicle weight was decreased significantly due to the intake of both drugs simultaneously compared to the control, tramadol, and vardenafil groups (Table 2).

Sperm count and morphology

While vardenafil administration caused a non-significant decrease in the sperm counts compared to the control group, tramadol induced a significant reduction in the count of sperm. The intake of both vardenafil and tramadol produced a significant reduction in sperm counts compared to the control and vardenafil groups (Table 3, Figure 2). The percent of sperm abnormalities, dead percent of sperms, tail defect percent, and amorphous sperms percent showed significant increases due to the intake of tramadol, vardenafil, and both drugs together as compared to the control (Table 3, Figure 2). The intake of both drugs together showed significant increases in the tail defect percent and amorphous sperms percent compared to the intake of tramadol or vardenafil (Table 3, Figure 2).

Male reproductive hormone profiles

Male reproductive hormone profiles (testosterone, LH, and FSH) were reduced significantly due to intake of tramadol, vardenafil, and both drugs as compared to the control (Table 4). The intake of both drugs together showed significant decreases in the reproductive hormone level profiles compared to vardenafil.

Testicular oxidative status

Administration of tramadol or vardenafil triggered significant elevation in MDA level compared to control. In contrast, both drugs significantly decreased GSH and CAT levels compared to the control (Table 5). Treatment of both drugs caused a significant rise in MDA concentration compared to tramadol and vardenafil. In contrast, both drugs significantly decreased GSH and CAT levels compared to tramadol and vardenafil (Table 5).

Histopathological findings

Control

Testicular slices from mice in the control group had seminiferous tubules that were properly structured and adequately packed with sperm. The seminiferous tubules were lined with stratified epithelia as spermatogonia, primary spermatocytes, spherical spermatids, and elongated spermatids. Blood capillaries and Leydig cells were seen in interstitial spaces between tubules (Figure 3).

Administration with tramadol

Seminiferous tubules shrank after tramadol administration, the tubular basement membrane disintegrated, and highly acidophilic material was deposited in the interstitium. The spermatogenic epithelium's lining was disrupted and arranged abnormally in mouse testis sections, with Leydig cells being depleted and germ cells and syncytial cells being shed into the tubular lumen. Some tubules seemed to have gaps between the spermatogenic cells lining them. This degraded tubule rarely contained any spermatids or sperm. Some disturbance was visible in the interstitial tissue, and some Leydig cells looked to have dissolved or vacuolated (Figure 4).

Administration with vardenafil

The seminiferous tubules underwent focal disorder after vardenafil administration, and the densities of spermatogenic cells were significantly reduced. Many of the seminiferous tubules were devoid of secondary spermatocytes, spermatids, and sperm. In the tubular lumina of numerous seminiferous tubules, shedding of the injured spermatocytes and spermatids was found. There were fewer interstitial cells in the inter-tubular connective tissue than in other tissues (Figure 5).

Administration with tramadol and vardenafil

Due to extensive necrotic and degenerative changes in the seminiferous tubules' wall, administration of tramadol and vardenafil revealed severe deterioration in the

seminiferous tubules. In addition, additional sections had degenerative spermatogonia and spermatocytes peeling and desquamating in the lumen of the seminiferous tubules. Leydig cells and other serious damage to the interstitial tissue were also present (Figure 6).

Morphometric Outcomes

Examination of the morphometric outcomes after

administering tramadol or vardenafil or both drugs simultaneously showed a significant reduction in the number of spermatogonia, the number of spermatocytes, and seminiferous tubule diameter as compared to the control (Table 6). The intake of tramadol and vardenafil showed non-significant changes in the morphometric outcomes compared to tramadol or vardenafil (Table 6).

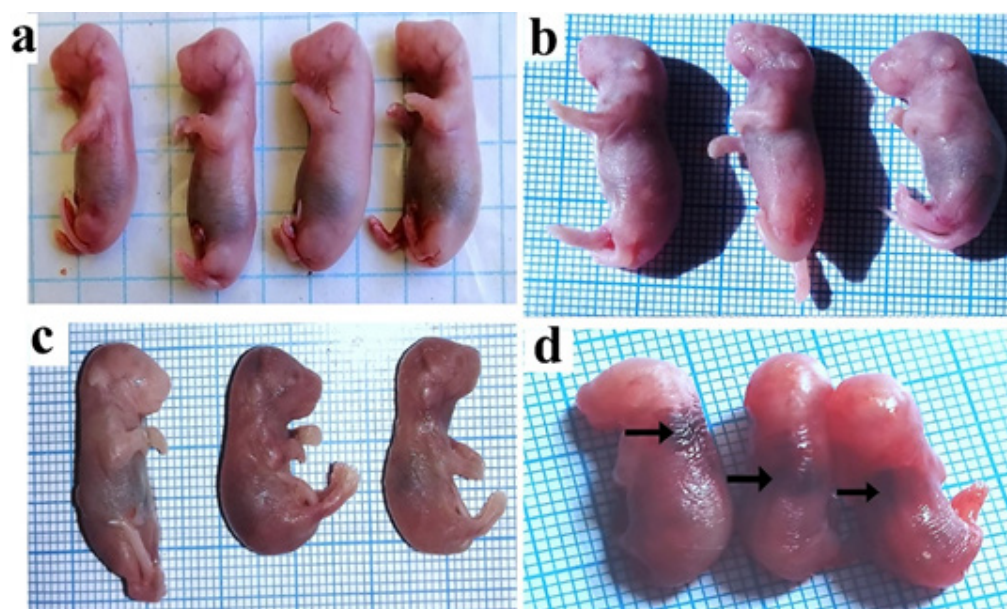


Fig. 1: Effect of tramadol and vardenafil on fetal mice. (a) control fetal with normal shape, (b) fetal of tramadol group, (c) fetal from vardenafil group, and (d) fetal of the combined group with retarded growth and skin hematoma (arrow).

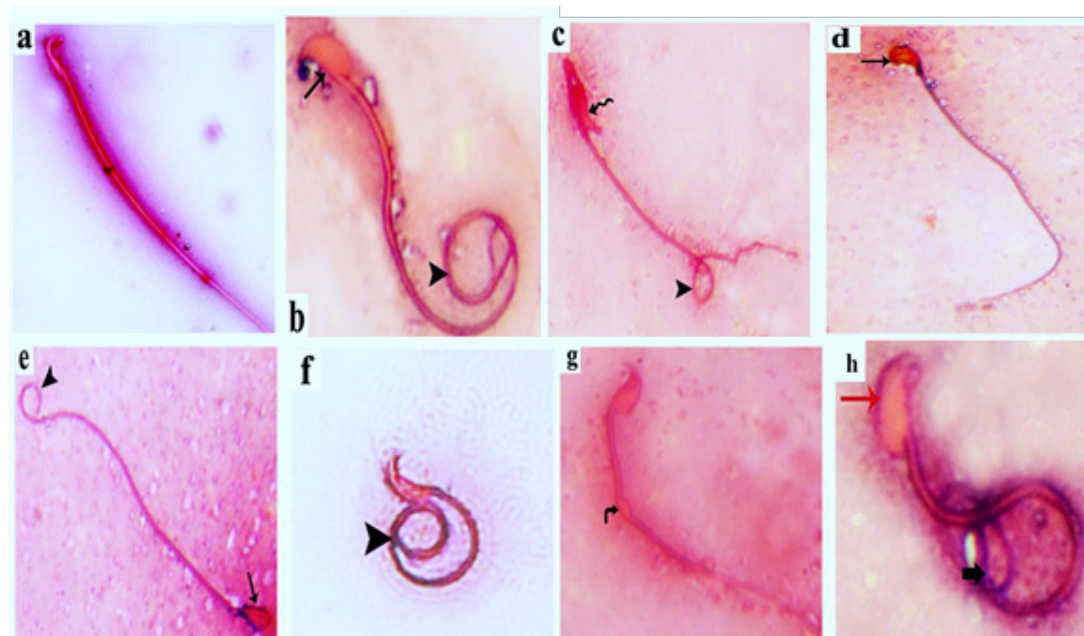


Fig. 2: Effect of tramadol and vardenafil on sperm abnormalities.

a) Sperm from the control group showed normal morphology of the head, mid-piece, and tail.

Sperm abnormalities:

b) Showed amorphous head (arrow) and coiled tail (head arrow).

c) Showed banana head without acrosome (zigzag arrow) and bent tail (head arrow).

d and e) Showed amorphous head (arrow) and bent tail (head arrow).

f) Showed coiled sperm (head arrow).

g) Showed cytoplasmic droplet (curved arrow).

h) Showed large head without hook (red arrow) and coiled tail (bold arrow)

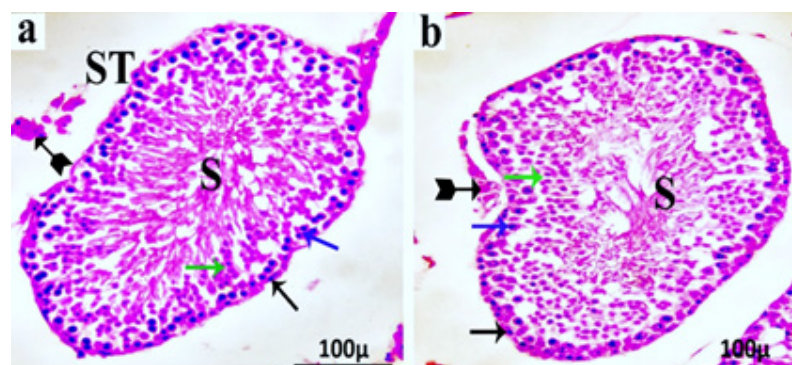


Fig. 3: Testis of the control group. Testis of the control group showed a group of seminiferous tubules (ST) lined by different types of germinal epithelium that rest on the regular intact basement membrane, spermatogonia (black arrow), primary spermatocyte (blue arrow), and spermatid (green arrow). Mature sperms in the lumen (S) and the interstitial tissue in between the tubules that contain Leydig cells (bifid arrow).

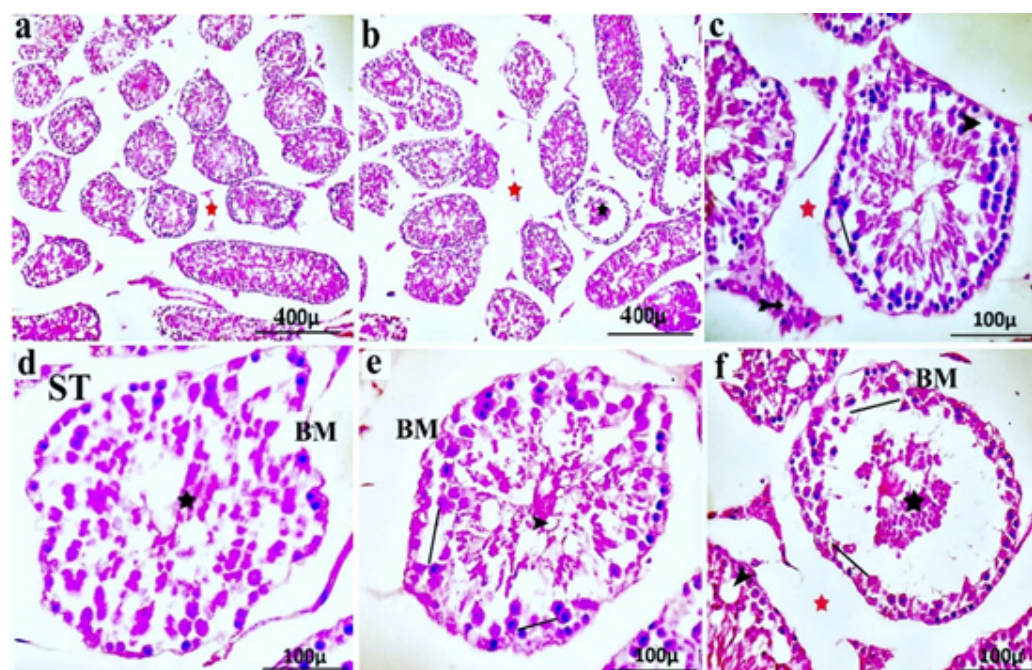


Fig. 4: Effect of tramadol on testicular tissue. A group of seminiferous tubules (ST) with severe disruption of their integrity and interruption of the basement membrane (BM) was observed. The lining of the germinal epithelium was markedly reduced (Line), and the cells were markedly dissociated from each other, leaving empty spaces (arrowhead). Widening gap between seminiferous tubules (red star). Germ cells and syncytial cells were sloughing into the tubular lumen (black star). Abnormal interstitial tissue with multiple vacuoles in place of Leydig cells destroyed (bifid arrow).

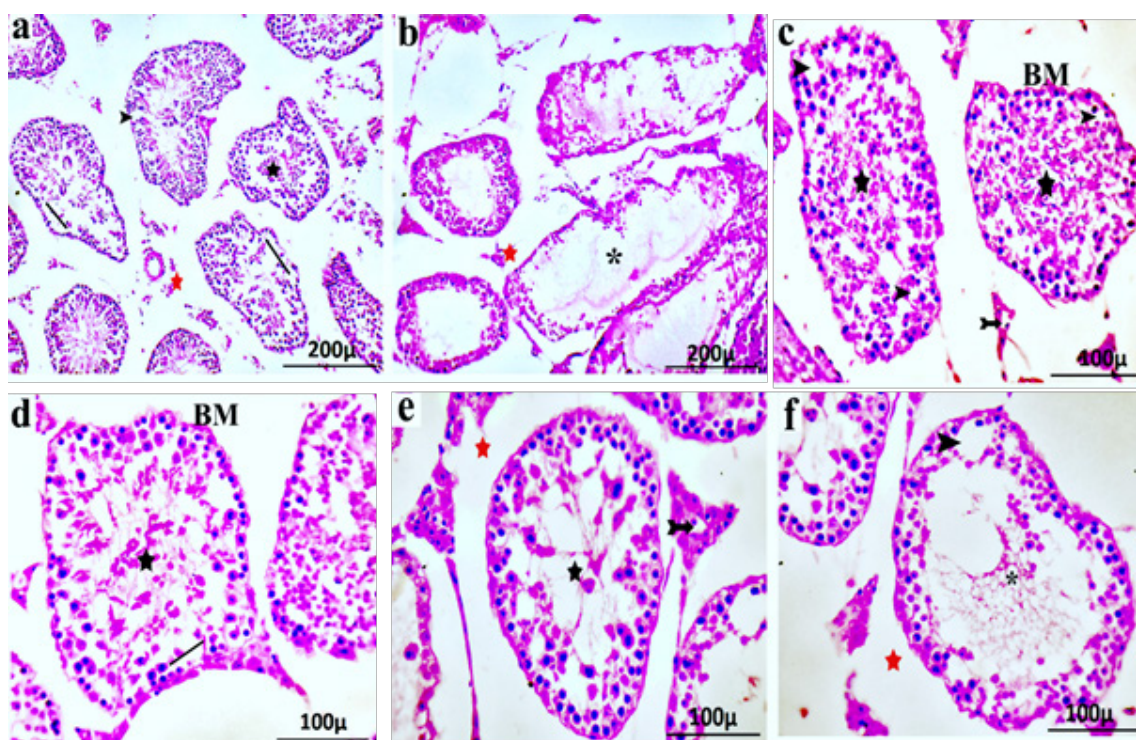


Fig. 5: Effect of vardenafil on testicular tissue. The spermatogenic cells were destroyed (line). Complete absences of mature sperms in some tubules (*) were observed. There were multiple spaces (arrowhead) with shrinkage and cell death. An interrupted basement membrane of the tubules (BM) was observed. Abnormal interstitial tissue was observed with multiple vacuoles in place of Leydig cells that were destroyed (bifid arrow). Germ cells and syncytial cells were sloughing into the tubular lumen (black star).

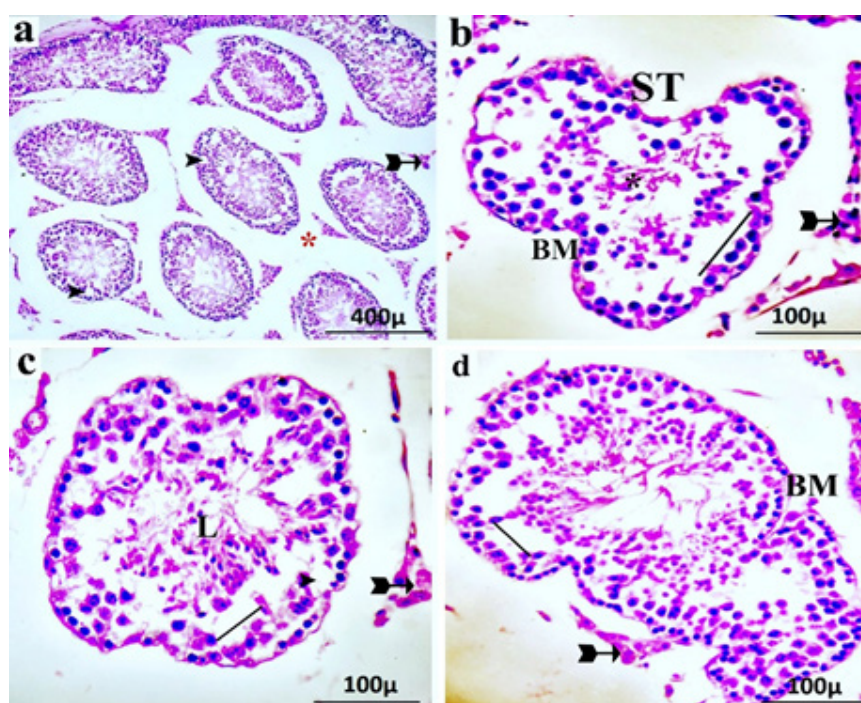


Fig. 6: Effect of tramadol and vardenafil on testicular tissue histopathology. Some seminiferous tubules (ST) contain many vacuoles (arrowhead), apparently wide interstitial spaces (red star). Spermatogenic cells are greatly disrupted (line). Germ cells and syncytial cells were sloughing into the tubular lumen (black star). The tubule lumen contains acidophilic remnants (L). Irregular basement membrane (BM). Affected Leydig cells (bifid arrow).

Table 1: Pregnancy outcomes

Parameters	Control	T	V	T+V
Fetal weight (g)	1.71±0.04	1.25±0.05 ^a	1.45±0.03 ^a	1.06±0.07 ^{a,b,c}
Mating index (%)	100	16.6	33.3	41

The data is expressed as the mean± standard error of the mean.

^a Significant difference as compared to control.

^b Significant difference as compared to Tramadol (T).

^c Significant difference as compared to Vardenafil (V).

Table 2: Effect of tramadol and vardenafil on reproductive organ weights (g)

	Control	T	V	T+V
Right testis	0.13±0.007	0.144±0.01	0.128±0.006	0.124±0.005
Left testis	0.13±0.007	0.134±0.01	0.114±0.006	0.116±0.002
Right epididymis	0.017±0.001	0.018±0.001	0.046±0.025	0.018±0.00
Left epididymis	0.017±0.001	0.02±0.001	0.019±0.001	0.018±0.00
Right seminal	0.07±0.004	0.08±0.01	0.07±0.007	0.064±0.007
Left seminal	0.072±0.003	0.078±0.003	0.076±0.006	0.05±0.004 ^{a,b,c}

The data is expressed as the mean± standard error of the mean.

^a Significant difference as compared to control.

^b Significant difference as compared to Tramadol (T).

^c Significant difference as compared to Vardenafil (V).

Table 3: Sperm morphology

	Control	T	V	T+V
Count ×10 ⁶ /mL	166.6±2.47	110.363±2.3 ^a	147.29±25.4	97.20±17.42 ^{a,c}
Abnormalities %	27.00±2.25	41.333±2.85 ^a	50.50±3.63 ^a	65.16±5.10 ^a
Dead %	59.00±2.30	73.17±1.27 ^a	65.67±6.33 ^a	72.33±3.66 ^a
Tail defect %	9.5±1.60	18.00±4.22 ^a	25.33±5.30 ^a	31.33±1.97 ^{a,b,c}
Amorphous %	17.50±0.76	17.50±0.76 ^a	25.83±1.21 ^a	33.83±4.92 ^{a,b,c}

The data is expressed as the mean± standard error of the mean.

^a Significant difference as compared to control.

^b Significant difference as compared to Tramadol (T).

^c Significant difference as compared to Vardenafil (V).

Table 4: Male reproductive hormone profiles

Parameters	Control	T	V	T+V
Testosterone (ng/ml)	7.270.59±	1.04±0.12 ^a	4.10±0.11 ^a	3.0±1.68 ^{a,c}
LH (mIU/ml)	4.660.68±	0.74±0.15 ^a	1.470.18±	1.31±0.33 ^{a,c}
FSH (mIU/ml)	4.36±0.98	0.32±0.16 ^a	1.90±0.73 ^a	0.94±0.39 ^{a,c}

The data is expressed as the mean± standard error of the mean.

^a Significant difference as compared to control.

^b Significant difference as compared to Tramadol (T).

^c Significant difference as compared to Vardenafil (V).

Table 5: Testicular oxidative status

Parameters	Control	T	V	T+V
MDA (nmol/g tissue)	136.96±9.46	827.51±11.80 ^a	530.40±63.41 ^a	1105.47±51.68 ^{a,b,c}
GSH (U/g protein)	637.4813.14±	129.391.56± ^a	182.21±7.56 ^a	99.00±4.10 ^{a,b,c}
CAT (U/mg protein)	1179.08±39.15	578.65±3.04 ^a	617.25±3.04 ^a	399.16±39.04 ^{a,b,c}

The data is expressed as the mean± standard error of the mean.

^a Significant difference as compared to control.

^b Significant difference as compared to Tramadol (T).

^c Significant difference as compared to Vardenafil (V).

Table 6: Morphometric Outcomes

Parameters	Control	T	V	T+V
Number of spermatogonia	41.7±2.38	23.9±1.98 ^a	27.25±3.63 ^a	22.05±1.87 ^a
Number of spermatocytes	58.9±1.29	16.85±1.94 ^a	19.35±2.19 ^a	14.65±1.87 ^a
Tubule diameter (µm)	222.68±2.46	144.64±4.68 ^a	148.01±8.04 ^a	140.05±8.94 ^a

The data is expressed as the mean± standard error of the mean. ^a significant difference as compared to the control.

DISCUSSION

Opioid exposure is one of the major causes of male infertility, Abdel-Moneim *et al.*^[13]. Tramadol and vardenafil are currently gaining popularity among teenagers all over the world. One opioid medicine widely used to treat cancer and chronic pain is tramadol, Minisy *et al.*^[14]. A 5-phosphodiesterase (PDE5) inhibitor called Vardenafil (VRD) is one of the medications used to treat erectile dysfunction Li *et al.*^[4].

The current study sought to determine how tramadol (4.16 mg/kg body weight) or/and vardenafil (46.8 mg/kg body weight) administered daily for 30 days would affect mouse testicular tissues and the effectiveness of sperm formation.

Examining the mating results revealed that when tramadol, vardenafil, or both medicines were taken simultaneously, the fetal weight and mating index % were much lower than they were in the control group.

DNA damage, chromosomal abnormalities, and impaired motility are a few examples of structural flaws or malfunction that can be indicated by aberrant sperm morphology according to Zhou *et al.*^[15].

The DNA in the sperm head can also have an impact on embryogenesis. Also connected to sperm DNA fragmentation is the existence of reactive oxygen species (ROS) and ROS-related DNA oxidative products, such as 8-hydroxy-deoxyguanosine (8-OH-dG). DNA fragmentation index and 8-OH-dG have been demonstrated to rise when sperm count falls, indicating that ROS and the pertinent byproducts may have a massive effect on sperm DNA preservation as stated by Loutradi *et al.*^[16].

The current study demonstrated that the weight of the testes and epididymis did not significantly change after tramadol or/and vardenafil intake when compared to control. Tramadol or/and vardenafil intake resulted in an insignificantly small decrease in the weight of the right seminal vesicle. Compared to the control, the weight of the left seminal vesicle significantly decreased when both medications were administered.

In an experiment by Ahmed and Kurkar^[17], 40 male Wistar albino rats weighing 160–205 g were used. For eight weeks, 40 mg/kg of Amadole (tramadol hydrochloride) was administered subcutaneously, three times per week. The relative weights of the testis and seminal vesicles in the treatment group and control group rats did not differ significantly.

According to research by Abdel latief *et al.* & Nna and Osim^[18,19], chronic tramadol treatment caused epididymis and testis to degenerate and shrinkage.

In contrast to the control group, male albino rats weighing 180 ± 10 g were given tramadol orally for 4 weeks and found that the relative testes' weight decreased significantly ($P < 0.05$) even though the relative epididymis weights remained the same.

The current study has shown that tramadol or vardenafil intake caused a significant decrease in sperm count, motility, and viability, as well as an increase in abnormalities, including an amorphous head and coiled tail in the treated mice. The fault in the sperm analysis was exacerbated when tramadol and vardenafil were administered simultaneously. These findings, which are corroborated by others, showed that these medicines had a negative impact on the analysis of sperm.

The long-term administration of sildenafil citrate (50 mg and 100 mg) to rats drastically reduced sperm counts and increased sperm abnormalities, according to Al-Fartosi^[20]. Because so many seminiferous tubules in the testis were destroyed, it is possible that less spermatogenesis and reduced sperm density in epididymis occurred in the treated group Hashish^[21].

Following the chronic dose of tramadol (10 and 20 mg/kg) three times a week for six weeks, Azari *et al.* showed a decrease in sperm motility^[22].

Researchers Ahmed & Kurkar; Abdel latief *et al.* and Masoud^[17,18,23] found that long-term tramadol administration had negative impacts on epididymal spermatozoa concentration, motility, and vitality in mice.

Since sperm morphology is a crucial criterion representing the level of maturity and normality of the sperm population in the ejaculate, El-Ghawet^[24] hypothesized that the drug has a strong negative effect on fertility. Primary spermatogenesis defects include flaws in the head and midpiece of sperm during testicular degeneration^[25].

Sildenafil (Viagra), tadalafil (Cialis), tramadol, and sildenafil + tramadol decreased sperm count and viability and increased the number of aberrant spermatozoa, according to Nna *et al.*^[26,27].

In the investigation of rats given a protracted overdose of sildenafil for 12 consecutive weeks at a level of 0.3 mg/kg wt/day, Fawzia *et al.* found that sperm count, and motility were negatively affected by sildenafil, Fawzia *et al.*^[28].

Male rats weighing 200–250 g was employed in Al-Fartosi study^[20]. They received 50 mg of sildenafil citrate (Viagra) for eight weeks. He claimed that changes in the expression of different cGMP receptors or the responsiveness of these receptors in the brain might be responsible for the negative impact on sperm analysis, which in turn results in damage to the tissue of the testis and failure of spermatogenesis.

Regarding examining reproductive hormones, the current study found that injection with tramadol, vardenafil, or both together led to a noticeably lower level of FSH, LH, and testosterone. These findings, which are corroborated by others, showed that these medicines had a negative impact on the release of sex hormones.

Youssef and Zidan^[29] found that male albino rats weighing 180–200 g had lower testosterone levels,

lutinizing hormone, and follicular stimulating hormone following tramadol administration.

Salah *et al.*^[2] discovered a decrease in blood testosterone, FSH, and LH levels and an increase in serum prolactin in mice receiving tramadol treatment.

Chronic tramadol use significantly impairs testicular tissue and affects male reproductive hormones by reducing serum levels of gonadotrophin and testosterone as confirmed by Attia *et al.* and Adelakun *et al.*^[3,30].

Numerous authors have explained the potential mechanism by which these drugs affect the male sex hormones.

Heidari^[31] chose 15 male Wistar rats weighing 250±15g and administered intraperitoneal methadone for 15 days at a dose of 0.5 mg/kg/day. The author noticed a drop in testosterone levels, which may have been brought on by Sertoli cells that had been destroyed.

Since LH causes the Leydig cells in the testis to secrete testosterone, it was known that the level of LH positively correlated with the concentration of testosterone Guyton and Hall^[32].

Both endogenous and exogenous opioids have been shown by Rubinstein *et al.*^[33] to induce hypogonadism via interacting with opioid receptors in the hypothalamus and pituitary gland. As a result, GnRH is also frequently liberated to a lesser extent, and the pituitary releases less LH and FSH, decreasing the amount of testosterone generated.

One of the potential mechanisms of opioid action, according to Yassa *et al.* and El-Gaafarawi *et al.*^[34,35], is the degeneration of Leydig and Sertoli cells in male albino rats via increased free radical generation. The shrinkage of the testes and a reduction in sperm cell production have been linked to a mild decline in gonadotropin output Haitham *et al.*^[25].

The hormonal reduction was attributed by Nna *et al.*^[26] to the low levels of TC and LDL-c (the substrates for testosterone production) observed following the treatment of sildenafil (10 mg/kg), tadalafil (10 mg/kg), tramadol (20 mg/kg), or sildenafil + tramadol.

A male's ability to reproduce and the health of his hypothalamic-pituitary-testicular axis (HPT) are closely related processes Gandhi *et al.*^[36]. A healthy HPT axis can be thrown off by various things, including underlying medical issues, recent surgery, and medications Whirlledge and Cidlowski^[37].

Tramadol's effects on the central nervous system may prevent pituitary gonadotrophins from being produced and released, which in turn causes them to be downregulated. Pituitary gonadotropins are necessary for starting and finishing spermatogenesis in the testes Moeen *et al.*^[38].

According to Abdel-Moneim *et al.*^[13], opioids can bind to certain receptors in the hypothalamus and pituitary gland

to interfere with the production of cortisol and androgen precursors and the pulsatile release of corticotrophin-releasing and adrenocorticotrophic hormones.

The injection of tramadol and vardenafil into adult male mice led to the generation of oxidative stress in the testicular tissues, according to the present study's analysis of antioxidant parameters. This effect was demonstrated by producing a much lower amount of CAT and GSH, two enzymatic antioxidants in the testes, and a significantly higher level of MDA in the testes compared to controls. The administration of both medications at once was found to increase oxidative stress.

Due to the high concentration of polyunsaturated fatty acids in the plasma membrane of spermatozoa, they are especially vulnerable to destruction by excessive quantities of reactive oxygen species, according to Agarwal and Parbakaran's^[39] research. Lipid peroxidation results in the structural destruction of the lipid matrix in the spermatozoa's membranes and are linked to decreased motility and spermatogenesis.

These findings align with those of El-Gaafarawi^[40], who discovered that the tramadol group had significantly higher serum MDA levels and higher levels of lipid peroxidation than the control group. These findings imply that lipid peroxidation may be a possible mechanism for the harmful effects of opioids at the cellular level.

After being administered for 30 days in a dose-dependent way, sildenafil (Viagra) was found to dramatically increase lipid peroxidation in the testes compared to the control group. The fact that Viagra is a testes-targeting medicine may be responsible for the enhanced lipid peroxidation in the testes Akintunde *et al.*^[41].

Although the presence of free radicals in testis is a physiologically normal occurrence, as demonstrated by Minisy *et al.*^[14], the rise in their creation induces oxidative stress and DNA damage in cells. Sperm dysfunction can be brought on by increased lipid peroxidation, altered membrane, and oxidative damage to the DNA of the sperm Salah *et al.*^[2].

This investigation showed that giving tramadol to male mice led to histological modifications in the testes. Examining the morphometric results after tramadol, vardenafil, or both medications were administered simultaneously revealed a significant decrease in the number of spermatogonia, spermatocytes, and seminiferous tubule diameter compared to the control.

Adult male rats were demonstrated to have decreased testicular function after receiving long-term subcutaneous tramadol administration (40 mg/kg) for 8 weeks. These effects may be due to increasing NO generation and oxidative stress brought on by the drug Ahmed and Kurkar and El Fatoh *et al.*^[17,42].

Youssef and Zidan^[29] found that acute and chronic tramadol administration in adult male albino rats caused

the seminiferous tubules to atrophy, resulting in several layers of vacuolated spermatocytes and little signs of spermatogenesis.

Tramadol was given to mice for an extended period, and Masoud^[23] found that this resulted in the loss of the majority of spermatogenic cells, degenerative alterations, disrupted seminiferous tubule architecture, and a decrease in spermatocytes, and rounded spermatid and Leydig cells.

In the study by Nna and Osim^[19], they examined the long-term usage of high doses of phosphodiesterase-5 inhibitors such as sildenafil and tadalafil, as well as tramadol or a sildenafil+ tramadol combination was shown to significantly alter the rat testis and epididymis, which had an adverse effect on sperm qualities and was difficult to reverse once therapy was stopped.

According to Tuorkey and Abdul Aziz^[43], spermatogenesis and spermiogenesis decreased as sildenafil citrate dosage increased. According to Eid *et al.*^[44], daily high dosages of tadalafil (20 mg) were shown to cause histologically deteriorating alterations in the rat seminiferous tubules, which decreased spermatogenesis.

The spermatogenic cells in several of the damaged seminiferous tubules displayed conspicuous multiple desquamations and vacuolar degeneration. These substances' effects on the testicles may be brought on by their unique toxic effects on the organ they are intended to affect as well as a hormonal imbalance in the hypothalamic-hypophysial-testicular axis, which may be brought on by excessive tramadol use Adelakun *et al.*^[3].

CONCLUSION

In Swiss mice, tramadol and/or vardenafil, the most widely used analgesic for the treatment of postoperative, cancer, or chronic neuropathic pain, and erectile dysfunction, are considered toxic reproductive agents due to their deleterious impact on the male reproductive organ. The reproductive toxicity of tramadol and/or vardenafil may be mediated by their ability to elevate the reactive oxygen species levels and imbalance the antioxidant system, induce histopathological changes in the testis, and affect the secretion of sex hormones.

ACKNOWLEDGMENTS

I want to express my gratitude to everyone who helped us finish this research at the Faculty of Science, Department of Zoology, Cairo University.

CONFLICT OF INTERESTS

There are no conflicts of interest.

AUTHOR CONTRIBUTIONS

Each author contributed equally to the data gathering and processing, article writing, reading, reviewing, and edits. The final draught of the paper was reviewed by each contributor and approved.

REFERENCES

1. Grond S, and Sablotzki A. Clinical pharmacology of tramadol. Clin Pharmacokinet [Internet]. 2004;43(13):879–923. Available from: <http://dx.doi.org/10.2165/00003088-200443130-00004>
2. Salah S, Wagih M, Zaki A, Fathy W, and Eid A. Long-term effects of tramadol on the reproductive function of male albino rats: an experimental biochemical and histopathological study. Middle East Fertil Soc J [Internet]. 2020;24(1). Available from: <http://dx.doi.org/10.1186/s43043-019-0003-0>
3. Adelakun SA, Ukwenya VO, and Akintunde OW. Vitamin B12 ameliorate Tramadol-induced oxidative stress, endocrine imbalance, apoptosis and NO/iNOS/NF-κB expression in Sprague Dawley rats through regulatory mechanism in the pituitary-gonadal axis. Tissue Cell [Internet]. 2022;74(101697):101697. Available from: <http://dx.doi.org/10.1016/j.tice.2021.101697>
4. Li J, Shi Q, Pu C, Tang Y, Bai Y and Yuan H, Li X, Dong Q, Wei, Q, Yuan J and Han P. Phosphodiesterase type 5 inhibitors for the treatment of post-nerve sparing radical prostatectomy erectile dysfunction in men. Sci Rep [Internet]. 2014;4(1):5801. Available from: <http://dx.doi.org/10.1038/srep05801>
5. Elkerdasy H and Mohamed A. The toxic effect of sildenafil citrate on adult albino rat testis and the possible protective role of royal jelly (histological and immunohistochemical study). Egypt J Histo [Internet]. 2019;42(2):381–92. Available from: <http://dx.doi.org/10.21608/ejh.2019.5632.1029>
6. Nair AB and Jacob S. A simple practice guide for dose conversion between animals and human. J Basic Clin Pharm [Internet]. 2016;7(2):27–31. Available from: <http://dx.doi.org/10.4103/0976-0105.177703>
7. Oderinde O, Noronha C, Oremosu A, Kusemiju T and Okanlawon OA. Abortifacient properties of aqueous extract of Carica papaya (Linn) seeds on female Sprague-Dawley rats. Niger Postgrad Med J. 2002;9(2):95–8. <http://dx.doi.org/10.4103/1117-1936.171036>
8. Lowe DG and Teffrey IM. Surgery Pathology Technique. Surgery Pathology Technique. 1990; BC Decker, Philadelphia, USA.
9. Goyal HO, Braden TD, Mansour M, Williams CS, Kamaleldin A and Srivastava KK. Diethylstilbestrol-treated adult rats with altered epididymal sperm numbers and sperm motility parameters, but without alterations in sperm production and sperm morphology. Biol Reprod [Internet]. 2001;64(3):927–34. Available from: <http://dx.doi.org/10.1095/biolreprod64.3.927>

10. Beutler E, Duron O and Kelly BM. Improved method for the determination of blood glutathione. *J Lab Clin Med.* 1963;61:882–8.
11. Aebi H. Catalase in *vitro*. *Methods Enzymol* [Internet]. 1984;105:121–6. Available from: [http://dx.doi.org/10.1016/s0076-6879\(84\)05016-3](http://dx.doi.org/10.1016/s0076-6879(84)05016-3)
12. Ohkawa H, Ohishi N and Yagi K. Assay for lipid peroxides in animal tissues by thiobarbituric acid reaction. *Anal Biochem* [Internet]. 1979;95(2):351–8. Available from: [http://dx.doi.org/10.1016/0003-2697\(79\)90738-3](http://dx.doi.org/10.1016/0003-2697(79)90738-3)
13. Abdel-Moneim WM, Fawzy M, Mohammed SA and Abdellah NZ. Association between male sex hormones and tramadol abuse. *Middle East Curr Psychiatr* [Internet]. 2022;29(1). Available from: <http://dx.doi.org/10.1186/s43045-022-00199-9>
14. Minisy FM, Shawki HH, El Omri A, Massoud AA, Omara EA and Metwally FG, Badawy MA, Hassan NA, Hassan NS and Oishi H. Pomegranate seeds extract possesses a protective effect against tramadol-induced testicular toxicity in experimental rats. *Biomed Res Int* [Internet]. 2020;2020:2732958. Available from: <http://dx.doi.org/10.1155/2020/2732958>
15. Zhou W-J, Huang C, Jiang S-H, Ji X-R, Gong F and Zhou WJ, Huang C, Jiang SH, Ji XR, Gong F, Fan LQ, Zhu WB. Influence of sperm morphology on pregnancy outcome and offspring in *in vitro* fertilization and intracytoplasmic sperm injection: a matched case-control study. *Asian J Androl.* 2021 Jul-Aug;23(4):421–428. https://doi.org/10.4103/aja.aja_91_20
16. Loutradi KE, Tarlatzis BC, Goulis DG, Zepiridis L, Pagou T and Chatziioannou E, Grimbizis G, Papadimas L and Bontis I. The effects of sperm quality on embryo development after intracytoplasmic sperm injection. *J Assist Reprod Genet* [Internet]. 2006;23(2):69–74. Available from: <http://dx.doi.org/10.1007/s10815-006-9022-8>
17. Ahmed MA and Kurkar A. Effects of opioid (tramadol) treatment on testicular functions in adult male rats: The role of nitric oxide and oxidative stress. *Clin Exp Pharmacol Physiol* [Internet]. 2014;41(4):317–23. Available from: <http://dx.doi.org/10.1111/1440-1681.12213>
18. Abdellatief RB, Elgamal DA and Mohamed EEM. Effects of chronic tramadol administration on testicular tissue in rats: an experimental study. *Andrologia* [Internet]. 2015;47(6):674–9. Available from: <http://dx.doi.org/10.1111/and.12316>
19. Nna VU and Osim EE. Testicular toxicity following separate and combined administration of PDE5 inhibitors and opioid: assessment of recovery following their withdrawal. *Andrologia* [Internet]. 2017;49(6). Available from: <http://dx.doi.org/10.1111/and.12669>
20. Al-Fartosi KG. Effect of long-term administration of sildenafil citrate (viagra) on some sperm characteristics and testis architecture of male rats. *Bas J Vet Res.* 2009;8(2):91–103. <http://dx.doi.org/10.33762/bvtr.2009.56909>
21. Hashish HA. Evaluation of histopathological and ultrastructural changes in the testis of tadalafil treated adult male albino rats. *J Histol Histopathol* [Internet]. 2015;2(1):18. Available from: <http://dx.doi.org/10.7243/2055-091x-2-18>
22. Azari O, Emadi L, Kheirandish R, Shafiei BH, Esmaili NMR and Faroghi F. The effects of long-term administration of tramadol on epididymal sperm quality and testicular tissue in mice. *Iranian Journal of Veterinary Surgery.* 2014;9(1):23–30.
23. Masoud R. Comparison between the effect of sildenafil citrate and tramadol on testis and sperm quality of male rats. *Suez Canal University Medical Journal* [Internet]. 2016;19(2):167–73. Available from: <http://dx.doi.org/10.21608/scumj.2016.116293>
24. El-Ghawet HA. Effects of tramadol on the reproductive function of wistar albino rats. *Eur J Exp Biol.* 2015;5(1):56–64.
25. Abd HH, Ahmed HA and Mutar TF. Moringa oleifera leaves extract modulates toxicity, sperms alterations, oxidative stress, and testicular damage induced by tramadol in male rats. *Toxicol Res (Camb)* [Internet]. 2020;9(2):101–6. Available from: <http://dx.doi.org/10.1093/toxres/tfaa009>
26. Nna VU, Akpan UP and Osim EE. Hyperprolactinemia contributes to reproductive deficit in male rats chronically administered PDE5 inhibitors (sildenafil and tadalafil) and opioid (tramadol). *Asian Pac J Reprod* [Internet]. 2016;5(5):381–6. Available from: <http://dx.doi.org/10.1016/j.apjr.2016.07.004>
27. Nna VU, Udefa AL, Ofutet EO and Osim EO. Testicular and epididymal histology of rats chronically administered high doses of phosphodiesterase-5 inhibitors and tramadol. *Niger J Physiol Sci.* 2017;32(1):55–61.
28. Goweder Fawzia M, Abu El-Nasr TM and El-Sayed AA. The effect of sesame intake on adult albino rat testis during sildenafil long-term administration. *J Basic Appl Zool* [Internet]. 2021;82(1). Available from: <http://dx.doi.org/10.1186/s41936-020-00202-x>
29. Youssef HS and Zidan AHM. Histopathological and Biochemical Effects of Acute and Chronic Tramadol Drug Toxicity on Liver, Kidney, and Testicular Function in Adult Male Albino Rat. *J of Medical Toxicol.* 2016;1(2):2471–7. <http://dx.doi.org/10.21767/2471-9>

30. Gamal N, Attia A, Sarhan N, Bakry O and Yassin H. Effect of tramadol on the male reproductive system and sexual health. *Menoufia Med J* [Internet]. 2021;34(1):1. Available from: http://dx.doi.org/10.4103/mmj.mmj_694_16
31. Heidari Z, Mahmoudzadeh-Sagheb H and Kohan F. A quantitative and qualitative study of rat testis following administration of methadone and buprenorphine. *Int J High Risk Behav Addict* [Internet]. 2012;1(1):12–5. Available from: <http://dx.doi.org/10.5812/ijhrba.4119>
32. Guyton AC and Hall JE. Textbook of medical physiology. Philadelphia, PA: W. B. Saunders; 2012.
33. Rubinstein AL, Carpenter DM and Minkof JR. Hypogonadism in men with chronic pain linked to the use of long-acting rather than shortacting opioids. *Clin J Pain*. 2013;29(10):840–5. <https://doi.org/10.1097/ajp.0b013e31827c7b5d>
34. Yassa HA, Dawood AEWA, Shehata MM, Abdel-Hady RH and Aal KMA. Subchronic toxicity of cannabis leaves on male albino rats. *Hum Exp Toxicol* [Internet]. 2010;29(1):37–47. Available from: <http://dx.doi.org/10.1177/0960327109354312>
35. El-Gaafarawi I, Hassan M, Fouad G and El-Komey F. Toxic effects of paroxetine on sexual and reproductive functions of rats. *The Egyptian Journal of Hospital Medicine*. 2005;21(1):16–32. <https://doi.org/10.21608/ejhm.2005.18045>
36. Gandhi J, Hernandez RJ, Chen A, Smith NL, Sheynkin YR and Joshi G, *et al.* Impaired hypothalamic-pituitary-testicular axis activity, spermatogenesis, and sperm function promote infertility in males with lead poisoning. *Zygote* [Internet]. 2017;25(2):103–10. Available from: <http://dx.doi.org/10.1017/S0967199417000028>
37. Whirledge S and Cidlowski JA. A Role for Glucocorticoids in Stress-Impaired Reproduction: Beyond the Hypothalamus and Pituitary. *Endocrinology*. 2013; 1;154(12):4450–68. <http://dx.doi.org/10.1210/en.2013-1652>
38. Moeen SS, Elhalwagy MEA and Ayaz NO. Alterations in oxidative stress and antioxidant in albino rats treated with individual and combined various food additives. *Int J Adv Res Biol Sci* [Internet]. 2018;5(6):118–23. Available from: <http://dx.doi.org/10.22192/ijarbs.2018.05.06.011>
39. Agarwal A and Prabakaran SA. Prevention of Oxidative Stress Injury to Sperm. *Journal of Andrology* [Internet]. 2005 Nov 12;26(6):654–60. <http://dx.doi.org/10.2164/jandrol.05016>
40. El-Gaafarawi II. Biochemical toxicity induced by tramadol administration in male rats. *Egypt J Hosp Med*. 2006;23:353–62. <https://doi.org/10.21608/ejhm.2006.17946>
41. Akintunde JK, Ajiboye JA, Siemuri EO, Oyelowo SB, Sunday OJ and Abam EO, *et al.* Sub-chronic treatment of sildenafil citrate (Viagra) on some enzymatic and non-enzymatic antioxidants in testes and brain of male rats. *J Pharm Drug Deliv Res*. 2012;1(2). <https://doi.org/10.4172/2325-9604.1000105>
42. El Fatoh MF, Sayed AE, Kamel MA, Ne A-H, Hussein MA and Salem GA. Some biochemical, neurochemical, pharmacotoxicological and histopathological alterations induced by long-term administration of tramadol in male rats. *Int J Pharm Sci*. 2014;4:565–71.
43. Tuorkey M and Aziz K. Effects of sex enhancing drugs on different organs in male Swiss Albino Mice. Values of Safety. *Scientific Reports*. 2012;1:133–45. <http://dx.doi.org/10.4172/scientificreports.133>
44. Eid AA, Badr El Dine FMM and Nabil IM. Histopathologic and ultrastructural changes in seminiferous tubules of adult male albino rats following daily administration of different doses of tadalafil. *Urology* [Internet]. 2016;90:89–96. Available from: <http://dx.doi.org/10.1016/j.urology.2015.12.038>

الملخص العربي

تأثير الترامادول و الفاردينافيل بمفرديهما ومعا على الخصوبة والأداء الإنجابي لذكور الفئران البالغة

مروة سمير عبد السلام^١، عبد الرحمن توفيق^١، عبد الرحمن سيد سلطان^٢، هبة علي عبد الرحمن^١

قسم علم الحيوان، كلية العلوم،^١ جامعة القاهرة،^٢ جامعة الأزهر (أسيوط)

المقدمة والهدف: يتناول هذا البحث دراسة تأثير الجرعة العلاجية من عقار الترامادول وهو من المواد الأفيونية الذي يعمل كمسكن للألام وعقار الفاردينافيل الذي يستخدم لعلاج مشاكل الوظائف الجنسية للذكور علي ذكور الفئران البالغين وأدائها التناسلي .

الطرق المستخدمة: فقد تم حقن الفئران لمدة ثلاثين يوما يوميا بكل عقار علي حدا وبالعقارين مع بعضهما ثم حدث تزاوج وتم فتح بطن الامهات قيصريا الحوامل في اليوم العشرين من الحمل وإستخراج الأجنة من الرحم وعدها وفحصها ثم تم تشريح الذكور وجمع عينات من الحيوانات المنوية وفحصها وتم فحص هرمونات الذكورة وإعداد شرائح نسيجية من الخصية كما تم قياس بعض جهود الأكسدة ومضاداتها في الانسجة السابق ذكرها.

النتائج: وتبين ان الترامادول والفاردينافيل لهما تأثير ضار جدا علي جودة الحيوانات المنوية وتعزيز التشوهات المورفولوجية وانخفاض في تركيز الهرمونات التناسلية وتشوهات في الشرائح النسيجية للخصية وقد أثرا العقارين علي قياسات جهود الأكسدة ومضاداتها وقد لوحظ نقص واضح في أوزان أجنة ووجود بعض التشوهات الخارجية.

الخلاصة: وعلى ذلك ينبغي تجنب تناول عقار الترامادول والفاردينافيل لفترة طويلة وإعطائه فقط إذا كانت فوائده تفوق مخاطره وبأقل جرعة فعالة ممكنة ولأقصر مدة حيث أن لهما تأثير ضار بشكل كبير علي جودة الحيوانات المنوية و علي الصحة الانجابية.