

## Histological Effects of Intermittent Fasting Concomitant with Levothyroxine Administration on the Thyroid Gland Structure of Adult Male Albino Rats

*Hala Taha Shalan, Mariam Asaad Amin and Enas Anwar Bekheet*

*Department of Anatomy and Embryology, Faculty of Medicine, Ain Shams University, Egypt*

### ABSTRACT

**Introduction:** Intermittent fasting is popularity and a promising approach for weight loss by daily restricted eating. Thyroid hormones controls body metabolism and accelerate the basal metabolic rate.

**Aim of this Work:** was designed to investigate the effect of intermittent fasting alone and when concomitant with levothyroxine on the histological characterization of the thyroid gland of the adult male albino rats.

**Material and Methods:** Twenty-four adult male albino rats were used and randomly divided into four equal groups. Group I (Control): Rats had free access to food and water. Group II (Fasting): Rats were deprived of food for 16 hrs daily with free access to water all over the day. Group III (levothyroxine): Each rat received levothyroxine (0.5µg/100g body weight /day) for three successive weeks via gastric tube and rats had free access to food and water all over the day. Group IV (Fasting +levothyroxine): Each rat received daily levothyroxine as in group III combined with food deprivation as in group II. At the end of the experiment, rats were sacrificed, and the thyroid glands were immediately obtained. The tissue samples were processed for paraffin and epon blocks. Thyroid sections were subjected to H&E, toluidine blue and Masson's Trichrome. Also, immunohistochemical study was carried out for the detection of apoptosis and parafollicular cells.

**Results:** The experimental intermittent fasting mildly affected the thyroid gland structure in comparison to the control group. In Levothyroxine treated group, most of follicles showed signs of degeneration in the form of their lining appeared vacuolated with dark nuclei and small or micro-follicles. While, fasting with levothyroxine showed marked obvious changes, flattened follicular cells with dark nuclei and vacuolated cytoplasm, desquamated foamy cells and scanty luminal colloid.

**Conclusion:** The obtained results revealed marked degenerative changes of thyroid gland when intermittent fasting combined with levothyroxine.

**Received:** 23 May 2021, **Accepted:** 25 July 2021

**Key Words:** Intermittent fasting, levothyroxine, thyroid gland.

**Corresponding Author:** Hala Taha Shalan, MD, Department of Anatomy and Embryology, Faculty of Medicine, Ain Shams University, Egypt, **Tel.:** +20 10 0197 0159, **E-mail:** halashalan1986@yahoo.com

**ISSN:** 1110-0559, Vol. 45, No. 4

### INTRODUCTION

Balanced nutrition is mandatory to maintain health and vitality. Also, there is not a particular mechanism controlling the amount of food needed for everyone. Increasing obesity rates in these years declares the importance of caloric restriction to prevent weight gain<sup>[1,2]</sup>. Intermittent fasting is a popularity and a promising approach for weight loss by daily restricted eating; this approach aims to decrease the daily calorie intake by 16 hrs. fasting and 8 hrs. eating<sup>[3,4]</sup>.

Changes in the hypothalamus–pituitary–thyroid axis have been reported during starvation. Food restriction has received little attention as a potential cause of the changes in thyroid hormones homeostasis<sup>[5]</sup>. Thyroid hormones control body metabolism and accelerate the basal metabolic rate. Thyroid dysfunction is known to be accompanied by oxidative stress through increasing free radicals' production and lipid peroxidation<sup>[6-8]</sup>.

It has been reported that in obese subjects, caloric deprivation to decrease the weight has been attributed to reduced thyroid hormones (T3 and T4) concentrations in

blood, indicating a lower metabolic rate. Consequently, another approach for weight reduction in euthyroid obese subjects is developed by receiving thyroid hormones to enhance weight loss. Many fatal side effects could result, such as muscle wasting and cardiac problems due to subclinical or overt hyperthyroidism<sup>[9,10]</sup>.

Levothyroxine is a manufactured form of the thyroid hormone (T4) that is used as a replacement or a supplemental therapy in hypothyroidism<sup>[11]</sup>. Therefore, the present work was designed to investigate the effect of intermittent fasting alone and when concomitant with levothyroxine administration on the histological characterization of the thyroid gland of the adult male albino rats.

### MATERIALS AND METHODS

#### Chemicals

Levothyroxine (Eltroxin)R was purchased in the form of tablets, each tablet contained 50 µg Levothyroxine (GlaxoSmithKline GmbH, Germany). Each tablet was dissolved in 50ml of distilled water.

## Animals

Twenty-four adult male albino rats were used, from 6-8 months age, weighting 180-200 gm, they were obtained and housed at the Medical research center of Faculty of Medicine-Ain-Shams University. Rats were kept in medium sized metal cages in a room temperature with regular dark/light cycles and good ventilation. All rats were kept under the same circumstances throughout the experiment. The experiment followed the guidelines of Ain Shams University Ethical Committee.

## Experimental Protocol

The twenty-four rats were randomly divided into four equal groups (6 rats/each):

**Group I (Control group):** This group served as a control and had free access to food and water all over the day for three successive weeks.

**Group II (Fasting group):** The rats were deprived of food for 16 hrs. (from 6 pm -10 am) daily with free access to water. During the non-fasting 8 hrs., rats had free access to food and water without caloric restriction<sup>[2]</sup> for three successive weeks.

**Group III (Levothyroxine group):** Each rat received 0.5µg/100g body weight/day of levothyroxine via gastric tube<sup>[12]</sup> with free access to food and water all over the day for three successive weeks.

**Group IV (Fasting +Levothyroxine group):** Each rat received 0.5µg/100g body weight/day of levothyroxine via gastric tube combined with food deprivation for 16 hrs. (from 6 pm -10 am) daily with free access to water for three successive weeks. During the non-fasting 8 hrs., rats had free access to food and water without caloric restriction.

At the end of the experiment, rats were anesthetized with ether inhalation. The thyroid glands were dissected out in two stages to avoid tissue damage. First, the neck was opened by a longitudinal incision, the fascia was removed, and the trachea was cut by a horizontal plane superior and inferior to the thyroid<sup>[13]</sup>. Then, subsequent dissection of the thyroid was carried out and used for the following studies. Disposal of animal remains was done according to the regulations of the animal house.

## Histological studies

For light microscopy study, specimens were fixed in 10% neutral-buffered formalin, dehydrated, embedded in paraffin, and then the sections were cut at 5µm and stained with Hematoxylin and eosin (H&E) for a routine histological examination<sup>[14]</sup>. Masson's trichrome stain was used on to clarify collagen fibers<sup>[15]</sup>.

Immunohistochemical stain for caspase-3 (indicator of apoptosis): sections were washed in phosphate-buffered saline for 5min and then incubated with antibody to cleaved caspase with a dilution of 1:200 (Invitrogen, Sweden AB Stockholm Sweden) overnight at 4°C, sections then were

washed and were incubated with secondary goat-anti-rabbit antibody (1:500) Invitrogen, Molecular Probes, Eugene, Oregon, USA) for 1h in room temperature. Slides were incubated in 3,3-diaminobenzidine for 10 min and then counterstained by Mayer's hematoxylin, dehydrated and mounted by dibutyl phthalate in xylene<sup>[16]</sup>.

Immunohistochemical stain for calcitonin was used as a detector of parafollicular cells. Calcitonin antibody (Rabbit polyclonal antibody) (DAKO A-576; Dako, Glostrup, Denmark) was used. The secondary antibody was rabbit/mouse immunoglobulins (Life Trade, Egypt) and 3,3-diaminobenzidine tetrahydrochloride was used as a chromogen. Tissue sections were counterstained with Mayer's hematoxylin<sup>[17]</sup>.

In addition, preparation of epon blocks for semithin sections: specimens were fixed in glutaraldehyde 2.5 % in phosphate buffer for 3hrs., tissue samples washed with phosphate buffer and post fixed in 1 % osmium tetra oxide, then dehydrated in alcohol and embedded in epon, semithin sections were cut to one um by L.K.B. ultra-microtome, picked up on a gelatinized glass slides and stained with toluidine blue<sup>[18]</sup>.

Paraffin and semithin stained sections were photographed after examination by light microscope (Olympus 268M microscope) equipped with an automatic photomicrographic camera system.

## Morphometrical study

Morphometric analysis was carried out using Image-J software on a computer connected to Olympus microscope equipped with a digital camera at the department of Anatomy (Faculty of Medicine-Ain Shams University). Six randomly chosen non overlapping fields in six sections obtained from six different rats from the same group were used for measuring the height of follicular cells in µm (on toluidine blue stained sections and only the cells with non-vacuolated cytoplasm were measured), area % of collagen fibers (on Masson trichrome stained sections) and the diameter of the central follicles in µm (on H&E., stained sections). Pixels were calibrated for actual measurements using a stage micrometer. The magnification used was x1000 for the cellular height, x400 for area % of collagen and x100 for the diameter of the follicles.

## Statistical analysis

Data analysis was performed (by MedCalc Version 11.1.1.0 Software, Belgium) and Microsoft Office Excel 2010 (Microsoft, USA) where analyses of variance (ANOVA test), mean, standard deviation (SD) and T-test were done. T-test result was considered nonsignificant when *P-value* > 0.05, significant when *P-value* ≤ 0.05 and highly significant when *P-value* ≤ 0.001.

## RESULTS

### *Histological Results*

**Control group (Group I):** H&E and toluidine-stained sections showed normal histological structure of the thyroid glands. They were consisted of follicles of variable sizes arranged in lobules with connective tissue in-between these lobules. Normal thyroid follicles filled with homogenous acidophilic colloid and were lined with a single layer of cubical follicular cells that had rounded nuclei. The interfollicular spaces showed connective tissue (cells and fibers) with blood capillaries (Figures 1,2). Semithin sections clarified the follicles were lined with a single layer of follicular cells that had spherical to oval vesicular nuclei. In some follicles, the para-follicular cells or C-cells with pale cytoplasm and rounded vesicular nuclei were noticed adjacent to the follicles (Figure 3).

Masson's Trichrome stained sections showed minimal amount of collagen fibers in the interfollicular areas and circling the blood capillaries (Figure 4).

Immunohistochemistry-stained sections of caspase-3 showed negative immune expression in the nuclei and cytoplasm of all follicular lining epithelium (Figure 5). While a few calcitonin immunoreactive C cells forming a part of the lining cells of the follicles and in between the follicles nearly in all examined section were detected (Figure 6).

**Fasting Group (Group II):** H&E-stained sections showed small sized follicles with preserved lobular architecture of follicles. Most follicles exhibited scanty colloid in their lumen. These follicles with single layer of cubical follicular cells exhibiting spherical nuclei and minimal vacuolated cytoplasm were observed in several sections (Figures 7,8). Semithin clarified the thyroid follicles with a single layer of follicular cells were seen. These lining follicular cells appeared with oval or irregular shaped vesicular nuclei with apparent mild decrease in the height of the cells. Also, Parafollicular cells with pale cytoplasm and dark nuclei were observed. Connective tissue and blood capillaries in between these follicles were easily demonstrated (Figure 9).

Masson's Trichrome stain showed apparent few collagen fibers within the interfollicular areas (Figure 10).

Immunohistochemistry-stained sections of caspase-3 showed negative immune expression in the nuclei and cytoplasm of all follicular lining epithelium (Figure 11). While a few scattered C-cells with weak brownish calcitonin immunoreaction nearly in all examined section were detected (Figure 12).

**Levothyroxine treated Group (Group III):** H&E-stained sections showed disruption of the normal glandular architecture, hardly detected lobular arrangement of the thyroid follicles and abundant adipose connective tissues in several examined sections. Most of these follicles

appeared small size (Figure 13). Some disrupted and fused follicles and some desquamated epithelial cells were easily demonstrated. Most of follicular cells exhibited dark rounded nuclei in addition to, some flattened follicular cells with flat dark nuclei in other follicles. In some section, few follicles with multiple layers of vacuolated follicular cell were observed. Congested capillaries between the follicles were detected. Colloidal lumen appeared partially vacuolated and with variable densities (Figure 14). Semithin sections showed follicular cells with irregular shaped nuclei and with apparent decrease in their height, and numerous parafollicular cells with pale cytoplasm and large pale nuclei (Figure 15).

Masson's Trichrome stain showed apparent scanty to absent collagen fibers within the interfollicular areas (Figure 16).

Immunohistochemistry-stained sections of caspase-3 showed positive caspase-3 expression in the nuclei and cytoplasm of most follicular lining epithelium (Figure 17). While numerous C- cells forming a part of the lining cells of the follicles and in between the follicles with intense positive brownish calcitonin immunoreaction (Figure 18).

**Fasting +Levothyroxine treated group (Group IV):** H&E-stained sections showed disruption of the normal glandular architecture and hardly detected lobular arrangement of follicles. Most of their follicles appeared small size with their follicular lumina were empty. While other follicles were filled with homogenous colloid of variable densities (Figure 19). Nearly all examined section showed follicles with remnants of colloid, other follicles with nearly depleted colloid and others with desquamated foamy cells in their lumina. Most of the follicular cells exhibited dark nuclei and vacuolated cytoplasm. Some flattened cells with flat dark nuclei were also seen. Few follicles with multiple layers of vacuolated follicular cells could be observed. Small blood capillaries were seen in between the follicular cells in several follicles (Figure 20). Semithin sections showed large thyroid follicle with irregular shaped nuclei and vacuolated cytoplasm and apparent decrease in the height of the cells. Other follicles were partially lined with more than one layer of follicular cells. Small parafollicular cells with pale nuclei and cytoplasm also were seen. small blood capillaries were noticed invading or penetrating the follicular lining epithelium (Figure 21).

Masson's Trichrome stain showed apparent scanty to absent collagen fibers within the interfollicular areas (Figure 22).

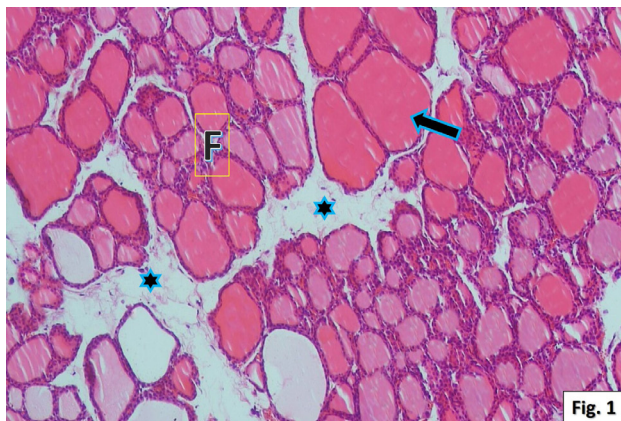
Immunohistochemistry-stained sections of caspase-3 showed strong positive caspase-3 expression in the nuclei and cytoplasm of most follicular lining epithelium (Figure 23). While, few parafollicular or C-cells forming a part of the lining cells of the follicles with positive brownish calcitonin immunoreaction (Figure 24).



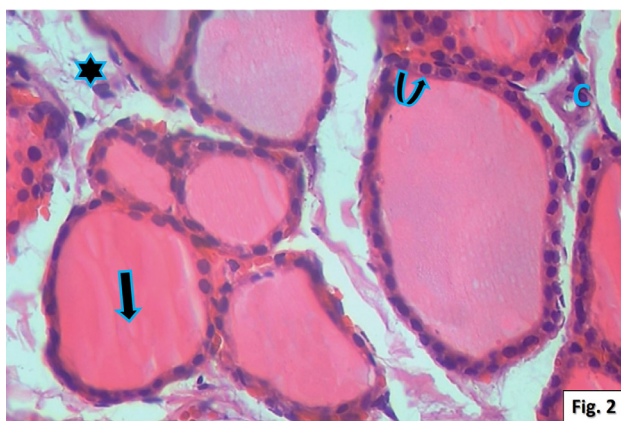
**Morphometric and statistical results**

Morphometric results were obtained by measuring the height of follicular cells in microns of all groups (Column Chart 1) and the statistical analysis revealed non-significant difference of the mean height of follicular cells of group II as compared to the control group (group I) with a *P-value* > 0.05. On the other, a highly significant difference between group I and group III and between group I and group IV were found with a *P-value* = 0.001 and a *P-value* < 0.001, respectively (Table 1).

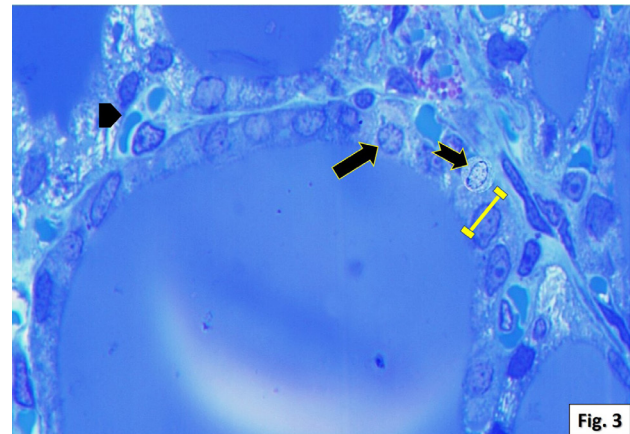
Moreover, the results obtained by the measures and the statistical analysis of area % of collagen fibers and the diameter of the follicles of all groups (Column Charts 2,3) revealed highly significant difference of the mean area % of collagen and the mean diameter of the follicles between group I and all the other groups with a *P-value* < 0.001 (Tables 2,3).



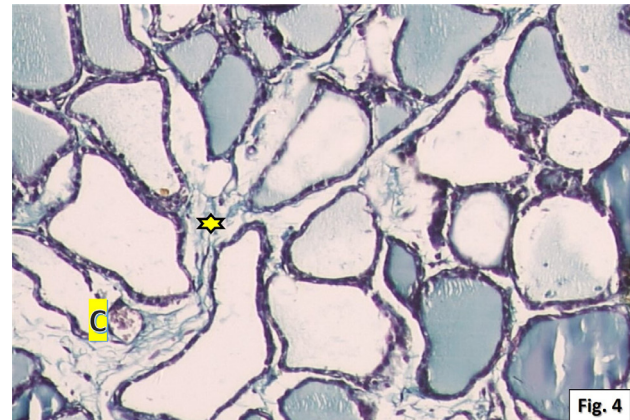
**Fig. 1:** A photomicrograph of a section in the thyroid gland of the control rat (group I) showing the lobules of the gland separated by connective tissue trabeculae (\*). The thyroid follicles (F) appear with variable sizes; large follicles are present especially at the periphery and filled with acidophilic colloid (arrow). (H & E, x100)



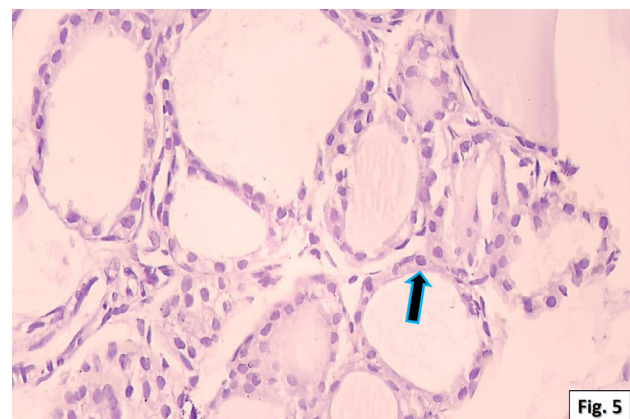
**Fig. 2:** A photomicrograph of a section in the thyroid gland of the control rat (group I) illustrating apparently normal thyroid follicles lined with a single layer of cubical follicular cells exhibiting spherical nuclei (curved arrow). The follicular lumens filled with homogenous acidophilic colloid (arrow). Notice the inter-follicular spaces with few cells (\*) and small blood capillaries (C). (H & E., 400)



**Fig. 3:** A photomicrograph of a semithin section in the thyroid gland of the control rat (group I) showing thyroid follicles were lined by a single layer of follicular epithelium. The lining follicular cells appear with rounded to oval vesicular nuclei (arrow). Notice the height of the follicular cell (line), the polygonal parafollicular cells with pale cytoplasm (notched arrow) and the small blood capillaries (arrowhead) in between the follicles. (Toluidine blue, x1000)

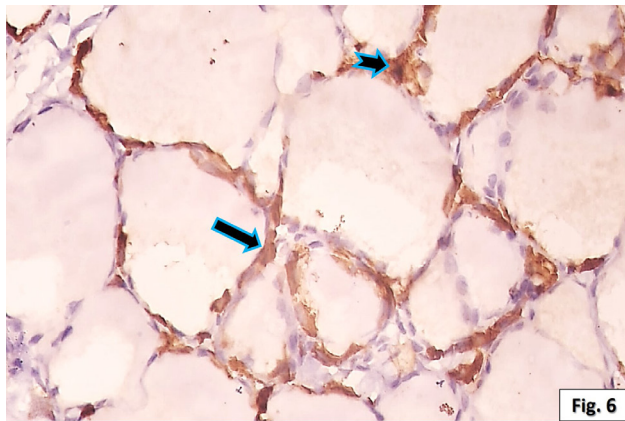


**Fig. 4:** A photomicrograph of a section in the thyroid gland of the control rat (group I) showing minimal amount of collagen fibers in interfollicular areas (\*) and around the blood capillaries (C). (Masson's Trichrome, x400)

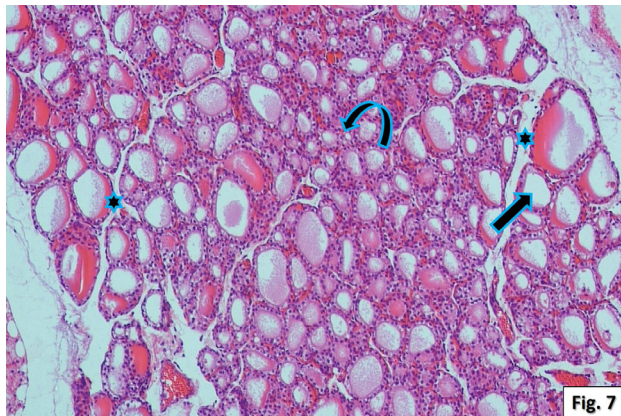


**Fig. 5:** A photomicrograph of a section in the thyroid gland of the control rat (group I) showing negative caspase-3 expression in the nuclei and cytoplasm of all follicular lining epithelium (arrow). (Caspase-3 immunostaining, 400)

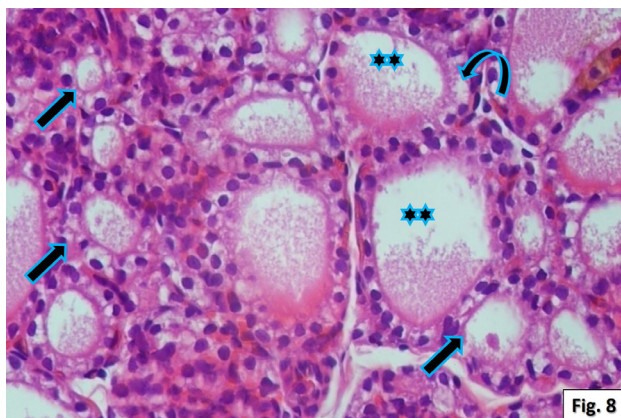




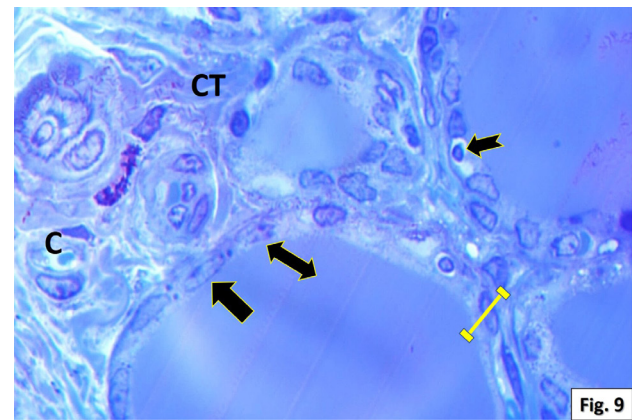
**Fig. 6:** A photomicrograph of a section in the thyroid gland of the control rat (group I) showing a few calcitonin immunoreactive C-cells (arrow) forming a part of the lining cells of the follicles and in between the follicles (notched arrow). (Anticalcitonin immunostaining, x400)



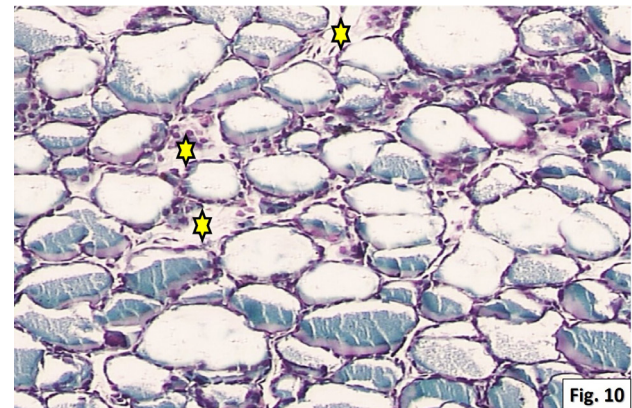
**Fig. 7:** A photomicrograph of a section in the thyroid gland of the fasting rat (group II) showing mostly small sized follicles (curved arrow) with scanty colloid (arrow). Notice the preserved lobular architecture of follicles that appeared separated by connective tissue (\*). (H & E., x100)



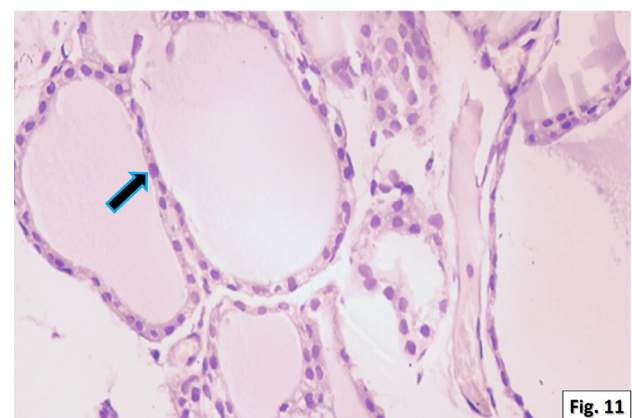
**Fig. 8:** A photomicrograph of a section in the thyroid gland of the fasting rat (group II) showing small sized follicles (arrows) and scanty luminal colloid (\*\*). These follicles were lined by a single layer of cubical follicular cells exhibiting spherical nuclei and minimal vacuolated cytoplasm (curved arrow) (H & E., x400)



**Fig. 9:** A photomicrograph of a section in the thyroid gland of the fasting rat (group II) showing thyroid follicles were lined by a single layer of follicular epithelium with apparent mild decrease in the height of the cells (line). The lining follicular cells appear with oval (arrow) or irregular shaped vesicular nuclei (double headed arrow). Parafollicular cells with pale cytoplasm and dark nuclei (notched arrows) are observed. Notice, connective tissue (CT) and blood capillaries (C) in between these follicles. (Toluidine blue, x1000)



**Fig. 10:** A photomicrograph of a section in the thyroid gland of the fasting rat (group II) showing apparent few collagen fibers in interfollicular areas (\*). (Masson trichrome, x400)



**Fig. 11:** A photomicrograph of a section in the thyroid gland of the fasting rat (group II) showing negative caspase-3 expression in the nuclei and cytoplasm of all follicular lining epithelium (arrow). (Caspase-3 immunostaining x400)



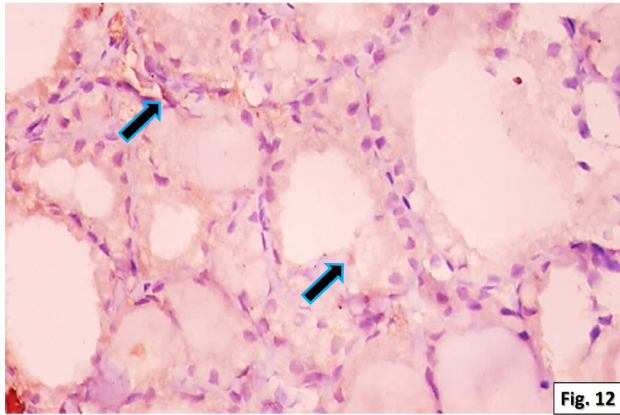


Fig. 12

**Fig. 12:** A photomicrograph of a section in the thyroid gland of the fasting rat (group II) showing few scattered C-cells forming a part of the lining cells of the follicles and in between the follicles with weak brownish positive calcitonin immunoreaction (arrows) (Anticalcitonin immunostaining x400)

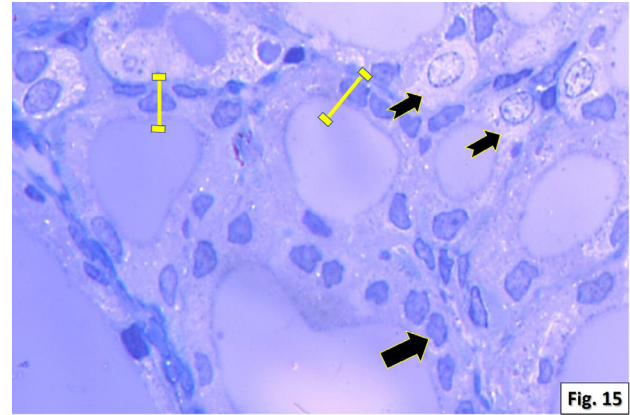


Fig. 15

**Fig. 15:** A photomicrograph of a section in the thyroid gland of the levothyroxine treated rat (group III) showing follicular cells with irregular shaped nuclei (arrow) and with apparent decrease in the height of the cells (lines). Notice numerous para-follicular cells with pale cytoplasm and large pale nuclei (notched arrows). (Toluidine blue, 1000)

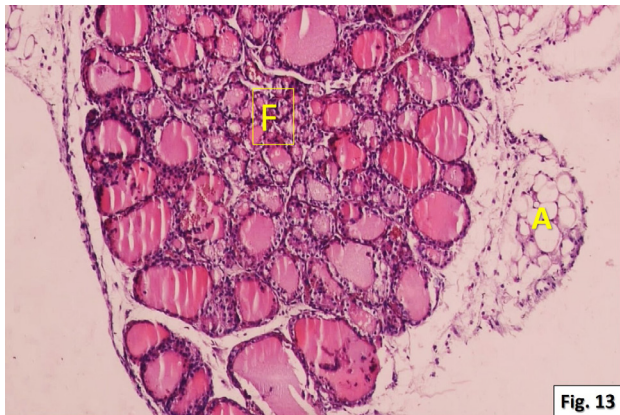


Fig. 13

**Fig. 13:** A photomicrograph of a section in the thyroid gland of the levothyroxine treated rat (group III) showing disruption of the normal glandular architecture, hardly detected lobular arrangement of follicles and abundant adipose connective tissues (A). Most of these follicles appear small size (F). (H& E., x100)

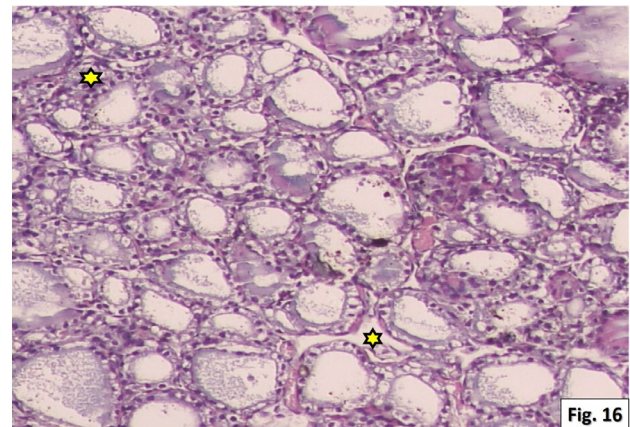


Fig. 16

**Fig. 16:** A photomicrograph of a section in the thyroid gland of the levothyroxine treated rat (group III) showing apparent scanty to absent collagen in the interfollicular spaces (\*). (Masson's Trichrome, x400)

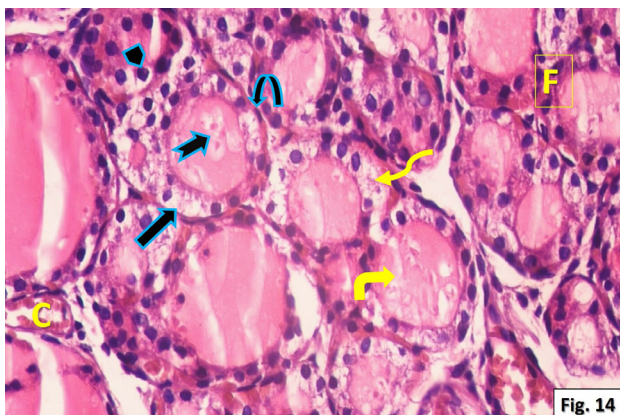


Fig. 14

**Fig. 14:** A higher magnification of the previous section showing disrupted and fused thyroid follicles (F) and some desquamated follicular cells (notched arrow) in the lumen. Dark rounded nuclei (arrowhead) and vacuolated cytoplasm (arrow) were seen in most of follicular cells in addition to, some flattened follicular cells with flat dark nuclei (curved arrow). Few follicles with multiple layers of vacuolated follicular cells (wavy arrow) were seen. Congested capillaries (C) were seen between the follicles. Notice, the colloidal lumen was partially vacuolated and with variable densities (right angled arrow). (H & E., x400)

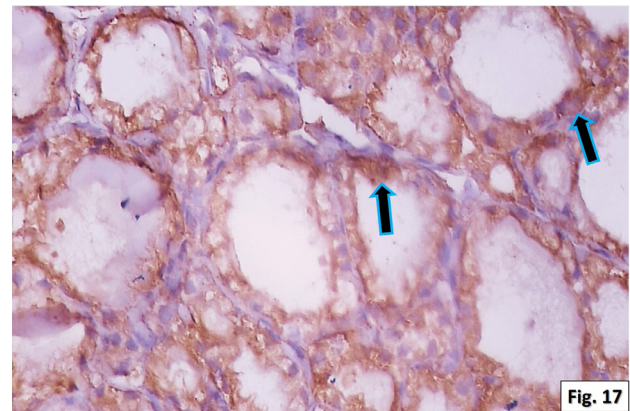
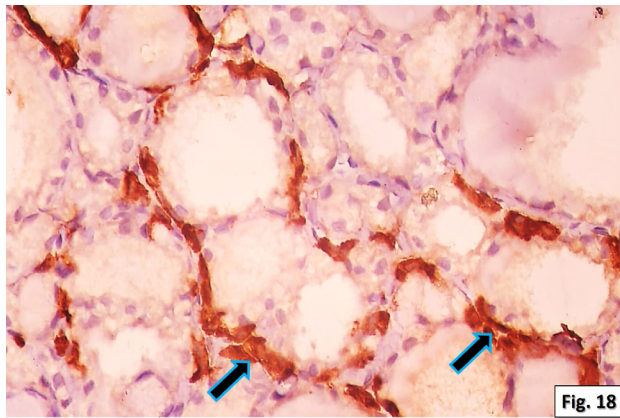


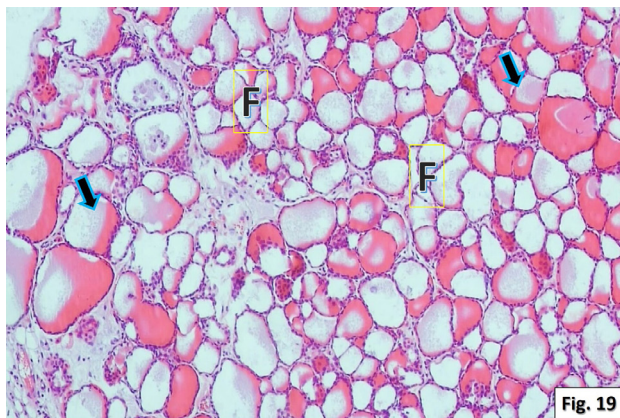
Fig. 17

**Fig. 17:** A photomicrograph of a section in the thyroid gland of the levothyroxine treated rat (group III) showing positive caspase-3 expression in the nuclei and cytoplasm of most follicular lining epithelium (arrow). (Caspase-3 immunostaining, x400)

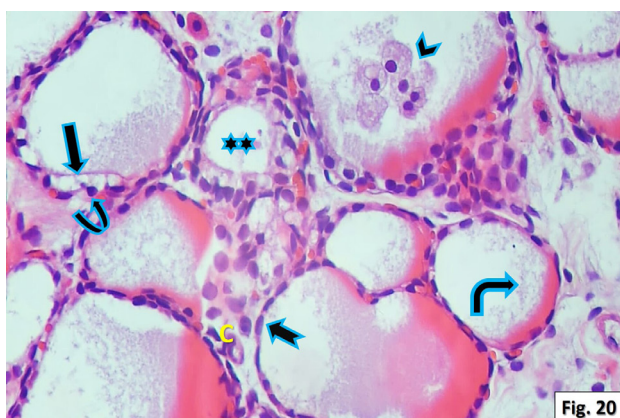




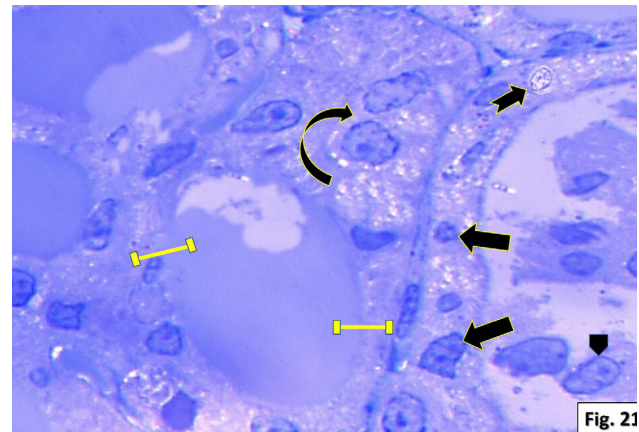
**Fig. 18:** A photomicrograph of a section in the thyroid gland of the levothyroxine treated rat (group III) showing numerous C- cells forming a part of the lining cells of the follicles and in between the follicles with intense positive brownish calcitonin immunoreaction (arrows). (Anticalcitonin immunostaining, x400)



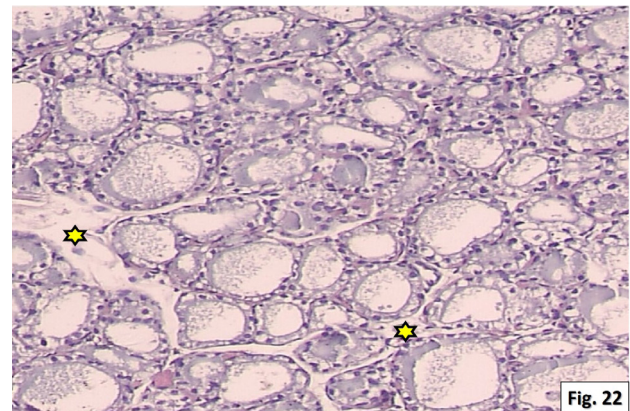
**Fig. 19:** A photomicrograph of a section in the thyroid gland of the fasting rats with levothyroxine (group IV) showing disruption of the normal glandular architecture and hardly detected lobular arrangement of follicles. Most of the follicles appeared small size with their empty follicular lumina (F). While other follicles were filled with homogenous colloid of variable densities (arrows). (H& E., x100)



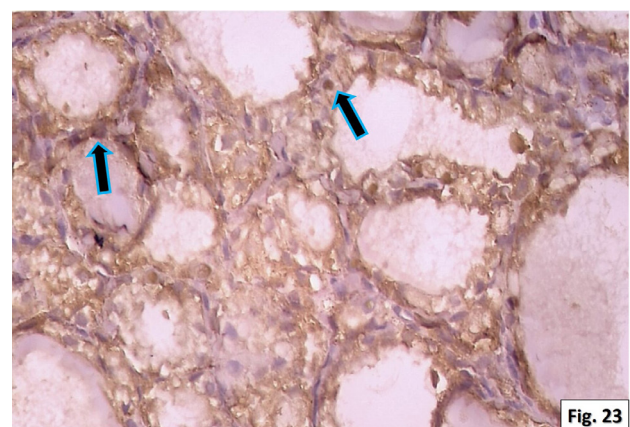
**Fig. 20:** A higher magnification of the previous section showing follicles with remnants of colloid (right angled arrow), other follicles with nearly depleted colloid (\*\*), and a follicle with desquamated foamy cells in its lumen (arrowhead). Flattened cells with flat dark nuclei (notched arrow) were seen in some follicles, other follicles with multiple layers of vacuolated follicular cells and dark rounded nuclei (curved arrow) were also seen. Notice, small blood capillaries (C) were seen in-between the follicular cells. (H & E., x400)



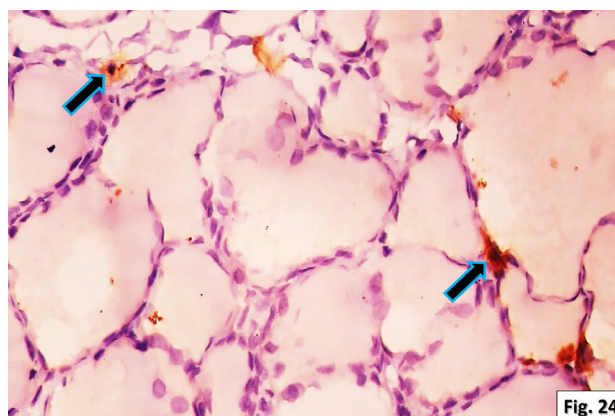
**Fig. 21:** A photomicrograph of a section in the thyroid gland of the fasting rats with levothyroxine (group IV) showing follicular cells with irregular shaped nuclei and vacuolated cytoplasm (arrows), apparent decrease in the height of the (lines), a follicle partially lined with more than one layer of follicular cells (curved arrow) and small parafollicular cell (notched arrow). Notice, the desquamated cells in the lumen (arrowhead). (Toluidine blue, x1000)



**Fig. 22:** A photomicrograph of a section in the thyroid gland of the fasting rats with levothyroxine (group IV) showing apparent scanty to absent collagen fibers in interfollicular areas (\*). (Masson's Trichrome, x400)



**Fig. 23:** A photomicrograph of a section in the thyroid gland of the fasting rats with levothyroxine (group IV) showing strong positive caspase-3 expression in the nuclei and cytoplasm of most follicular lining epithelium (arrows). (Caspase-3 immunostaining, x400)



**Fig. 24:** A photomicrograph of a section in the thyroid gland of the fasting rats with levothyroxine (group IV) few parafollicular or C- cells forming a part of the lining cells of the follicles with positive brownish calcitonin immunoreaction (arrows). (Anticalcitonin immunostaining, x400)

**Table 1:** Comparing the height of follicular cells in  $\mu\text{m}$  of the groups II-III and IV to the control group

	Group I (control)	Group II (fasting)	Group III (levothyroxine)	Group IV (levothyroxine+ fasting)
The height of follicular cells in $\mu\text{m}$ (mean $\pm$ standard deviation)	8.48 $\pm$ 0.7	8.07 $\pm$ 0.4	6.19 $\pm$ 0.9	4.8 $\pm$ 0.7
T test	Between Group I&II		P= 0.09*	
	Group I&III		P = 0.001**	
	Between Group I&IV		P= 0.0001***	

(\* non-significant *P*-value, (\*\*) significant *P*-value and (\*\*\*) highly significant *P*-value.

**Table 2:** Comparing area % of collagen fibers of the groups II-III and IV to the control group

	Group I (control)	Group II (fasting)	Group III (levothyroxine)	Group IV (levothyroxine+ fasting)
Area % of collagen fibers (mean $\pm$ standard deviation)	6.6 $\pm$ 1.0	4.3 $\pm$ 0.5	2.8 $\pm$ 0.6	1.6 $\pm$ 0.5
T test	Between Group I&II		P= 0.0002***	
	Group I&III		P = 0.0008***	
	Between Group I&IV		P= 0.0001***	

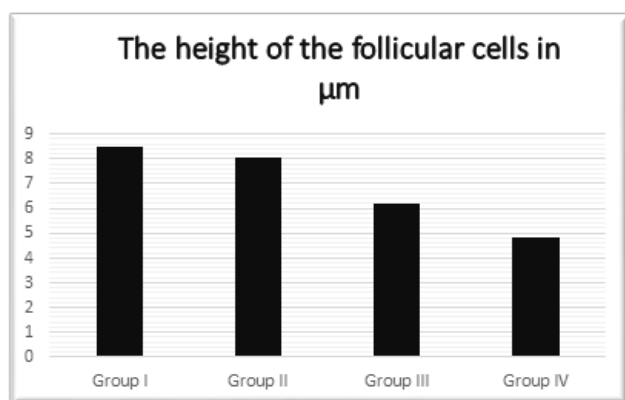
(\*\*\*) highly significant *P*-value.

**Table 3:** Comparing the diameter of the follicles in  $\mu\text{m}$  of the groups II-III and IV to the control group

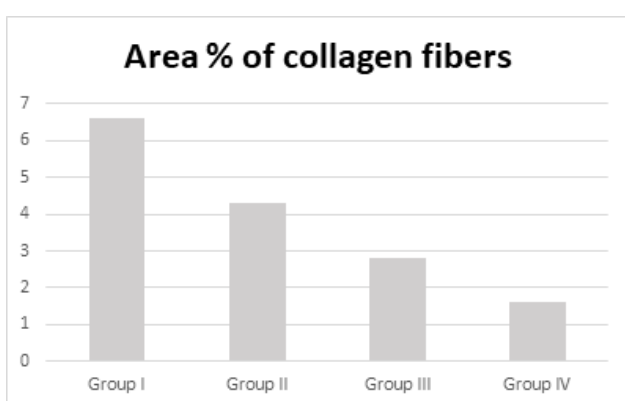
	Group I (control)	Group II (fasting)	Group III (levothyroxine)	Group IV (levothyroxine+ fasting)
The diameter of the follicles in $\mu\text{m}$ (mean $\pm$ standard deviation)	75,6 $\pm$ 3.7	45.8 $\pm$ 3.3	29.8 $\pm$ 5.7	28.1 $\pm$ 4.4
T test	Between Group I&II		P= 0.0001***	
	Group I&III		P = 0.0004***	
	Between Group I&IV		P= 0.0001***	

(\*\*\*) highly significant *P*-value.

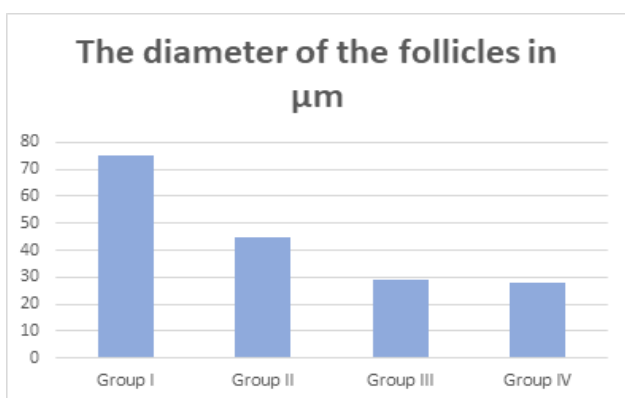




**Column chart 1:** morphometric comparison between the four groups as regard; the height of follicular cells in µm.



**Column chart 2:** morphometric comparison between the four groups as regard; the area % of collagen fibers.



**Column chart 3:** morphometric comparison between the four groups as regard; the diameter of the follicles in µm.

## DISCUSSION

The thyroid gland is a unique endocrine gland; it is superficially located in the neck. It is specialized in production, storage, and release of thyroid hormones (T4 & T3). The thyroid hormone is responsible for growth and development, regulation of basal metabolic rate and cellular metabolism<sup>[19,20]</sup>. Obesity and thyroid abnormalities are common conditions closely linked together from clinical and molecular viewpoints. This relation has become clinically relevant in the context of an unprecedented increase in the prevalence of obesity worldwide<sup>[21]</sup>.

Intermittent fasting is a dietary regimen where intervals of regular food intake are interrupted by intervals of fasting to reduce the energy value<sup>[22]</sup>. The popularity of intermittent fasting has grown tremendously over the past few years. Benefits of intermittent fasting may include weight loss, reduced inflammation and improved blood sugar balance<sup>[21]</sup>. Controversy continues as to whether thyroid hormone administration has beneficial or harmful effects in euthyroid obese subjects undergoing caloric deprivation<sup>[10]</sup>.

Levothyroxine (LT4) is the treatment of choice when the diagnosis of persistent thyroid hormone deficiency is confirmed<sup>[22,23]</sup>. Bearing in mind that the structure of any organ closely reflects the state of its function. So, this work was designed to investigate the effect of intermittent fasting alone and when concomitant with levothyroxine on the histological characteristics of thyroid gland, as both could be used for weight reduction.

The results of the present study clarified mild histological changes of the thyroid gland of the fasting group in comparison to the control group. The gland showed small sized follicles with preserved lobular architecture. Most follicles exhibited scanty colloid in their lumen with minimal vacuolated cytoplasm in some follicular cells. Semithin clarified the lining follicular cells which appeared with oval or irregular shaped vesicular nuclei. Also, the parafollicular cells appeared with pale cytoplasm and dark nuclei. Morphometrical and statistical analysis revealed non-significant decrease of the mean height of follicular cells of the fasting group and highly significant decrease of the mean diameter of the thyroid follicles in comparison to the control group.

Few studies have been carried out to demonstrate the histopathological changes of thyroid gland that occurred with intermittent fasting. A reduction in the colloid amount and the diameter of rats' follicles during starvation was reported, and the explanation was that starvation resulted in decrease in the thyroid gland function with subsequent decrease in serum thyroid hormones level. Since the thyroid hormones are unique, unlike other hormones, they are iodine incorporated as an active component and the amount of iodine is dependent on the ingested food<sup>[24-26]</sup>. Also, food restriction was reported to increase a corticosterone level which in turn decreases 5-monodeiodinase that is a peroxidase enzyme involved in the activation of thyroid hormones<sup>[27]</sup>.

Moreover, this study revealed few collagen fibers in the interfollicular areas in the fasting group which confirmed by the statistical analysis that revealed highly significant decrease of the mean area % of collagen fibers of the fasting group in comparison to the control group. The collagen fibers within the extracellular matrix represent the most abundant extracellular protein which is produced by the fibroblasts. This finding coincided with other researchers who stated that fasting is known to be accompanied by a decrease in collagen biosynthesis. This mechanism assumes inhibition of prolydase enzyme which plays a crucial role

in up-regulation of collagen metabolism. The mechanism of fasting induced inhibition of prolydase enzyme activity is not known<sup>[28]</sup>.

Regarding the immunohistochemical analyses of the current study, thyroid sections from fasting rats revealed no evidence of apoptosis when examined by Caspase-3. Other results were in harmony with the previous finding, intermittent fasting attenuated apoptosis of myocardial cells in Doxorubicin induced cardiotoxicity<sup>[29]</sup>. In addition, anticalcitonin antibody is a best detector for parafollicular cells. Different section showed weak positive brownish cytoplasmic reaction in parafollicular cells. Parafollicular or C- cells, apart from its role is calcium homeostasis, they are probably also involved in the intra-thyroidal regulation of follicular cells. This hypothesis was supported by different features, such as their characteristic 'parafollicular' position, their predominance in the central region of the thyroid lobe and their implication in the secretion of different regulatory peptides<sup>[17]</sup>. C- cells secrete calcitonin which opposes the action of parathormone by reducing the blood calcium level. Calcitonin is a hormone independent in its secretion on pituitary gland and depends mainly on the level of serum calcium<sup>[30]</sup>. Previous studies showed that the serum calcium concentration have been decreased with intermittent fasting<sup>[31]</sup>.

In this experiment, the rats treated with levothyroxine showed mild to moderate histological changes of the thyroid glands when compared to the control group. The thyroid gland showed disruption of the normal glandular architecture, hardly detected lobular arrangement of the thyroid follicles and abundant adipose connective tissues in several examined sections. Most of follicles appeared small size. Some disrupted and fused follicles and some desquamated epithelial cells were detected. Most of follicular cells exhibited dark rounded nuclei in addition to, some flattened follicular cells with flat dark nuclei in other follicles. In some section, few follicles with multiple layers of vacuolated follicular cell were observed. Congested capillaries between the follicles were also detected. Colloidal lumen appeared partially vacuolated and with variable densities. Semithin sections clarified follicular cells with irregular shaped nuclei and numerous parafollicular cells with pale cytoplasm and large pale nuclei. Morphometrical and statistical analysis revealed highly significant decrease of the mean height of follicular cells and of the mean diameter of the thyroid follicles in comparison to the control group. The previous findings were in agreement with Rajab *et al.*<sup>[32]</sup> who referred similar findings to the absence of cytoprotective effects of thyroid stimulating hormone signals because of the high circulating levels of external thyroid hormones. Expectedly in the present study, administration of levothyroxine elevated the circulating T4, resulting in feedback inhibition of thyroid releasing and thyroid stimulating hormones release, at levels of hypothalamus and pituitary, respectively. Thus, according to the obtained results the thyroid gland in the hormone-treated groups were under-stimulated and in the

arrest state. Cytologically, the disorganization, follicular cells with vacuolated cytoplasm and dark nuclei as well as reduced epithelial height, provide further evidence for the functional quiescence of the thyroid after thyroid hormone treatment. All findings were in accordance with other studies<sup>[32,33]</sup>. Moreover, this study showed few or absent collagen fibers in the interfollicular spaces which confirmed by the statistical analysis that revealed highly significant decrease of the mean area % of collagen fibers of levothyroxine treated group in comparison to the control group. The previous findings were in agreement with Rajab *et al.*<sup>[32]</sup> who reported, desquamated cells inside the follicular lumen, decreased height of follicular cells, fusion of some thyroid follicles and decrease in interfollicular connective tissue with external thyroid hormones administration in rats.

On the other hand, the immunohistochemical analyses of the current study, thyroid sections from levothyroxine rats revealed strong evidence of apoptosis when examined by Caspase-3. Positive immune reactions of most follicular cells were clearly observed. A previous study reported an increase in follicular cells apoptosis with external thyroid hormones administration in rats and concluded that external T3 and T4 cause marked damage of thyroid follicles in euthyroid glands even after short-term therapy<sup>[32]</sup>. While other sections showed intense positive anticalcitonin immunoreaction in numerous parafollicular cells. These parafollicular cells thought to have a role in the regulation of follicular cells function through the secretion of regulatory peptides, suggesting a possible interrelationship between the two endocrine cell types. Therefore, induced changes in the follicular cell's activity may affect the parafollicular cells<sup>[17]</sup>.

Furthermore, in this experiment, the fasting rats treated with levothyroxine revealed marked histological alterations compared to control and other groups. Multiple follicles appeared degenerated with desquamated epithelial cells in their lumen. Multiple follicles showed either diminished or depleted colloid. Some follicles appeared coalesced, follicles showed flattened cells with dark nuclei and other follicles were lined with multiple few cellular layers. Cytoplasmic vacuolations and dark apoptotic nuclei were seen. Also, small, few parafollicular cells were observed. To our knowledge, by reviewing the literature, no studies were concerned about this combination (fasting + levothyroxine) effects on the thyroid structures.

However, thyroid gland histological alterations in group IV might be attributed to the reduced level of antioxidant with increased reactive oxygen species that has been reported with starvation<sup>[34,35]</sup>. However, all these previous findings might be elucidated and attributed to the oxidative stress which caused severe DNA damage, caspase activation, mitochondrial dysfunction, and formation of reactive oxygen species (ROS) that has been reported with starvation<sup>[34,35]</sup>.



Also, in this study, evidence suggesting hypoactive gland was the depleted colloid of most follicles and the marked reduction of collagen fibers in the interfollicular areas. In addition to the morphometrical and the statistical results that revealed highly significant decrease in the mean height of the follicular cells, the mean area % of collagen fibers, and the mean diameter of the follicles in comparison to the control group. Lee *et al.*<sup>[36]</sup> reported similar finding that were representing a distinctive sign of inactive thyroid gland. Some focal follicular cell hyperplasia was detected in the present study that could be a direct result of increased apoptosis as indicated by caspase-3 immunoreactivity when compared with the control. These apoptotic cells were shed into the follicular lumen. In contrast to the control, the rare occurrence of desquamated cells was noted. This finding in the absence of hormonal treatment is related to normal basal thyroid cells turnover, thyroid gland maintains its mass homeostasis by sustained basal proliferation and apoptosis<sup>[37]</sup>.

In the same concern, cytoplasmic vacuolations seen in the follicular cells in the two groups (III& IV) could be attributed to ROS induced cellular membranes insults, which ultimately generate self-sustaining lipid peroxidation and enhanced transport of water and electrolytes into the cells<sup>[38]</sup>. Also, these vacuolations can be attributed to the presence of swollen mitochondria or endoplasmic reticulum<sup>[39]</sup>.

Moreover, other sections of group IV showed faint, weak positive anticalcitonin immunoreaction of few scattered parafollicular cells. Three possible explanations were considered regarding the changes in parafollicular cells with alterations in the follicular cells, firstly, TSH indirectly regulates parafollicular cells, secondly the follicular cells directly affect parafollicular cells function and thirdly, the parafollicular cells affect follicular cells activity<sup>[34,40]</sup>. In addition, Ahmed *et al.*<sup>[41]</sup> stated that levothyroxine induced lipid peroxidation leading to cellular damage. Also, the same histological changes were observed with decreased TSH level which has the main stimulative effect on the structure and the function of the thyroid gland. Its stimulative effect on the follicular cells is thought to be modulated a variety of molecules, some of them released from the parafollicular cells<sup>[42-44]</sup>.

## CONCLUSION

The obtained results in this study revealed mild structural alterations of the thyroid gland with intermittent fasting, moderate alterations with levothyroxine administration and marked degenerative changes when combined levothyroxine with fasting. All of these changed were observed and evaluated by both light and immunohistochemical studies. Further research on the effect of intermittent fasting on hyperactive and hypoactive thyroid gland is strongly recommended. The obtained results should contribute to better understanding of the possible side-effects and safety of therapy with other manufactures of the thyroid hormones.

## CONFLICT OF INTERESTS

There are no conflicts of interest.

## REFERENCES

1. Kaya SO, Emre Kaya, Gur S, Yilmaz S and Celiker IM: Effect of starvation and refeeding on spermatological parameters and oxidative stress in rats. *International journal of health sciences*, (2019) 7(2): 21-28.
2. Malinowski B, Zalewska K, Węsierska A, Sokółowska MM, Socha M, Liczner G, Pawlak- Osińska K *et al.* Intermittent fasting in cardiovascular disorders-an overview. *Nutrients*, (2019) 11: 1-18.
3. Craft S, and Rhoads K: *Insulin resistance syndrome and Alzheimer's disease in insulin resistance syndrome and neuropsychiatric disease*. 1st Edition CRC Press, (2008) 104-118.
4. Rajpal A and Ismail-Beigi F: Intermittent fasting and 'metabolic switch': Effects on metabolic syndrome, prediabetes and type 2 diabetes *Obes. Metab.*, (2020) 22:1496-1510.
5. Vries EM, Beeren HC, Ackermans MT, Kalsbeek A, Fliers E and Boelen A: Differential effects of fasting vs food restriction on liver thyroid hormone metabolism in male rats. *Journal of Endocrinology*, (2015) 224: 25-35.
6. Krishna TS, Priyanka DP and Rao EV: Alteration of serum uric acid concentration in subjects with hypothyroidism. *IJABT*, (2011) 2 (2): 1428-1433.
7. Teixeira PF, Borges P dos Santos and Pazos-Mour CC: The role of thyroid hormone in metabolism and metabolic syndrome. *Thera Adv Endocrinol Metab*, (2020) 11: 1-33.
8. Abdel-Fattah ME, Mohammed SM and Mohammed IH: Effects of experimentally induced thyroid dysfunctions on cardiac contractility in adult male albino rats. *Al-Azhar Assiut medical journal*, (2015) 13(3):143-151.
9. Adler SM and Wartofsky L: The nonthyroidal illness syndrome. *Endocrinol Metab Clin North Am.*, (2007) 36:657-672.
10. Kaptein EM, Beale E, and Chan LS: Thyroid hormone therapy for obesity and nonthyroidal illnesses: A systematic review. (2009) 94(10): 3663-3675.
11. Benvenga S and Carlé A: Levothyroxine formulations: pharmacological and clinical implications of generic substitution. *Adv Ther.* (2019) 36: 59-71.
12. Purohit A and Purohit A: Eltroxin like mimic action of with ania somnifera leaf extract in hypothyroid-induced rats, (2018) 11(11): 280-284.

13. Zbucki RŁ, Winnicka MM, Sawicki B, Szynaka B, Andrzejewska A, Puchalski Z. Alteration of parafollicular (C) cells activity in the experimental model of hypothyroidism in rats. *Folia Histochem Cytobiol.* (2007) 45:115–121.
14. Drury RAB and Wallington EA: *Carleton's Histological Technique*. 5th ed. Oxford, New York, Toronto: Oxford University Press, (1980) p.237.
15. Chandler N: The Masson trichrome staining methods in routine laboratory use. *Stain technology journal*, (2009) 8(3): 101-110.
16. Stenberg L, Kanje M, Dolezal K and Dahlin LB: Expression of activating transcription factor 3 (ATF 3) and caspase 3 in Schwann cells and axonal outgrowth after sciatic nerve repair in diabetic BB rats. *Neuroscience letters*, (2012) 515 (1): 34-38.
17. Martín-Lacave I, Borrero MJ, Utrilla JC, Fernández-Santos JM, de Miguel M, Morillo J, *et al.*: C cells evolve at the same rhythm as follicular cells when thyroidal status changes in rats. *J Anat.*, (2009) 214:301–309.
18. Bancroft JD and Stevens A. *Theory and practice of histological techniques*. 4th ed. Churchill Livingstone: Edinburgh, (1996) P. 433-472.
19. Mullur R, Liu YY, and Brent GA: thyroid hormone regulation. *Physiol Rev.*, (2014) 94: 355–382.
20. Cacic-Milosevic M, Korać A and Davidović V: Methimazole-induced hypothyroidism in rats: effects on body weight and histological characteristics of thyroid gland. *Jugoslovenska Medicinska Biohemija*, (2004) 23:143–147.
21. Santini F, Marzullo P, Rotondi M, Ceccarini G, Pagano L, Ippolito S, *et al.* Mechanisms in endocrinology: the crosstalk between thyroid gland and adipose tissue: signal integration in health and disease. *Eur J Endocrinol.* (2014)171(4): 137-152.
22. Chaker L, Bianco AC, Jonklaas J and Peeters RP. Hypothyroidism. *Lancet.* (2017) 390:1550-1562.
23. Biondi B, Bartalena L, Chiovato L, Lenzi A, Mariotti S, Pacini F. *et al.* Recommendations for treatment of hypothyroidism with levothyroxine and levotriiodothyronine: a 2016 position statement of the Italian Society of Endocrinology and the Italian Thyroid Association. *J Endocrinol Invest.* (2016)39 (12):1465–1474.
24. Hill JO, Wyatt HR and Peters JC: Energy balance and obesity. *Circulation*, (2012) 126 (1):126-32.
25. Omidi A, Namazi F, Jabire S, Afsar M, Honarmand M and Nazifi S: The effects of starvation and refeeding on oxidative stress parameters (MDA, SOD, GPx), lipid profile, thyroid hormones and thyroid histopathology in male wistar rats. *International Archives of Medicine*, (2016) 9(238): 1-10.
26. Castillo VA, Rodriguez MS, Alia JC and Pisarev MA: Morphological changes in thyroid glands of puppies fed a high iodine commercial diet. *The international J. of applied research*, (2003) 2(4):156- 162.
27. Leatherland JF and Farbridge KJ: Chronic fasting reduced the response of thyroid to growth hormone, TSH & alters the growth hormone related changes in hepatic 5-monodeiodinase activity in rainbow trout *Onchorrhynchus mykiss*. *J. general & comparative Endocrin.*, (1992) 87(3):342-353.
28. Cechowska-Pasko M, Palka J and Bańkowski E: Fasting-induced inhibition of collagen biosynthesis in rat skin. A possible role for phosphoenolpyruvate in this process. *Molecular and Cellular Biochemistry*, (2004) 265: 203–208.
29. Farag EA and Sabry MM: Intermittent Fasting Attenuates Apoptosis, Modulates Autophagy and Preserves Telocytes in Doxorubicin Induced Cardiotoxicity in Albino Rats: A Histological Study. *EJH*, (2020) 43(3) 663-668.
30. Shah JP: Thyroid carcinoma: epidemiology, histology, and diagnosis. *Clin Adv Hematol Oncol.*, (2015)13 (4):3-6.
31. Al-Kotobe MF, Abbass MT, Marbut MM: The effect of Ramadan fasting on serum calcium, phosphorus, and Parathyroid hormone in normal healthy subjects. *Tikrit Medical Journal*, (2006) 12(1): 58 -60.
32. Rajab NMA, Ukropina M and Cacic-Milosevic M: Histological and ultrastructural alterations of rat thyroid gland after short-term treatment with high doses of thyroid hormones. *Saudi journal of biological science*, (2017) 24: 1117-1125.
33. Sellitti DF and Suzuki K: Intrinsic Regulation of Thyroid Function by Thyroglobulin. *Thyroid*, (2014) 24(4):625-638.
34. Domenicali M, Caraceni P, Vendemiale G, Grattagliano I, Nardo B, Dall'Agata M and Bernardi M: Food deprivation exacerbates mitochondrial oxidative stress in rat liver exposed to ischemiareperfusion injury. *J Nutr.*, (2001) 131(1):105-110.
35. Rahman K: Studies on free radicals, antioxidants, and cofactors. *Clin Inter Aging*, (2007) 2(2):219-236.
36. Lee J, Yi S, Kang YE, Kim HW, Joung KH, Sul HJ *et al.* Morphological and functional changes in the thyroid follicles of the aged murine and humans. *J. Pathol Transl Med.*, (2016) 50(6): 426–435.
37. Tamura, M., Kimura, H., Koji, T., Tominaga, T., Ashizawa, K., Kiriama, T. *et al.* Role of apoptosis of thyrocytes in a rat model of goiter. A possible involvement of Fas system. *Endocrinology*, (1998)139, 3646–3653.



38. Abdul-Hamid M and Moustafa N. Protective effect of curcumin on histopathology and ultrastructure of pancreas in the alloxan treated rats for induction of diabetes. *The Journal of Basic and Applied Zoology* (2013) 66: 169–79.
39. Ruwhof C and Drexhang HA: Iodine and thyroid autoimmune disease in animal models. *Thyroid*, (2001): 427-436.
40. Dadan J, Zbucki RL, Sawicki B, Winnicka MM and Puchalski Z: Activity of the thyroid parafollicular (C) cells in simple and hyperactive nodular goiter treated surgically preliminary investigations. *Folia Morphol.*, (2003) 62: 443-445.
41. Ahmed SB, Moghazy AM, Ahmed-Farid OA and Esebry HA: Effects of aqueous extract of polyherbal formulation against hyperthyroidism induced by L-thyroxin in a rat model. *Biomedical Research and Therapy*, (2018) 5(12):2876- 2887.
42. Rajkovic V, Matavulj M and Johansson O: Light and electron microscopic study of the thyroid gland in rats exposed to power-frequency electromagnetic fields. *J Exp Biol.*, (2006) 209: 3322-3328.
43. Ahrén B: Regulatory peptides in the thyroid gland-a review on their localization and function. *Acta Endocrinol*, (1991)124: 225-232.
44. Felsenfeld AJ and Levine BS: Calcitonin, the forgotten hormone: does it deserve to be forgotten? *Clin Kidney J.*, (2015) (2):180-187.

## الملخص العربي

## التأثيرات النسيجية للصيام المتقطع المصاحب لإعطاء الليفوثيروكسين على بنية الغدة الدرقية للذكور البالغين من الفئران البيضاء

هاله طه شعلان، مريم أسعد أمين، ايناس أنور بخيت

قسم التشريح وعلم الأجنة ، كلية الطب ، جامعة عين شمس ، مصر

**مقدمة:** يعد الصيام المتقطع شائعاً ونهجاً واعداً لفقدان الوزن عن طريق الأكل المقيد يومياً. تتحكم هرمونات الغدة الدرقية في التمثيل الغذائي للجسم وتسرع معدل الأيض الأساسي.

**الهدف:** يهدف هذا العمل إلى دراسة تأثير الصيام المتقطع وحده وعندما يتزامن مع الليفوثيروكسين على بنية الغدة الدرقية لذكور الفئران البيضاء.

**المواد والطرق:** تم استخدام أربعة وعشرين من ذكور الفئران البيضاء البالغ وزنها 180-200 جم ، قسمت عشوائياً إلى أربع مجموعات متساوية. المجموعة الأولى (المجموعة الضابطة): كان للفئران حرية الوصول إلى الغذاء والماء. المجموعة الثانية (مجموعة الصيام): حرمت الفئران من الطعام لمدة 16 ساعة. يومياً مع حرية الوصول إلى المياه طوال اليوم. المجموعة الثالثة (مجموعة الليفوثيروكسين): تلقى كل فأر 0,5 ميكروجرام / 100 جرام من وزن الجسم يوميا من الليفوثيروكسين لمدة ثلاثة أسابيع متتالية عبر أنبوب معدي ، وكان للفئران حرية الوصول إلى الطعام والماء طوال اليوم. المجموعة الرابعة (مجموعة الليفوثيروكسين + الصيام): تلقى كل فأر الليفوثيروكسين يومياً كما في المجموعة الثالثة مع الصيام كما في المجموعة الثانية.

**النتائج:** أظهر العمل الحالي أن الصيام المتقطع يؤثر بشكل طفيف على بنية الغدة الدرقية مقارنة بالمجموعة الضابطة. أظهر إعطاء الليفوثيروكسين جزيئات صغيرة الحجم ومعظمها كان مبطناً بخلايا ذات سيتوبلازم رغوي مفرغ مع نوى داكنة. بينما أظهر تناول الليفوثيروكسين المصاحب للصيام المتقطع تغيرات ملحوظة في الخلايا الجريبية. أظهر البعض منهم السيتوبلازم الرغوي المفرغ وأظهر البعض الآخر خلايا مفلطحة ذات نوى مسطحة داكنة. تم الكشف أيضا عن تواجد بعض الخلايا الرغوية المنفصلة مع القليل من الغرّوان الدرقي في تجويف الجريبات.

**الخلاصة:** كشفت النتائج التي تم الحصول عليها في هذه الدراسة عن تغيرات نسيجية ملحوظة في تركيب الغدة الدرقية عند الجمع بين ليفوثيروكسين والصيام المتقطع.